

**OPERATIVE TREATMENT OF CHONDRAL DEFECTS IN THE
GLENOHUMERAL JOINT: A SYSTEMATIC REVIEW**

Christopher E.T. Gross MD¹, Peter N. Chalmers MD¹, Jaskarndip Chahal MD
FRCSC¹, Geoffrey S. Van Thiel MD MBA^{1,2}, Brian J Cole MD MBA¹, Bernard R.
Bach MD¹, Anthony A Romeo MD¹

¹Department of Orthopaedic Surgery, Rush University Medical Center, Chicago, IL

²Rockford Orthopedic Associates, Rockford, IL

ABSTRACT

INTRODUCTION

The objective of this study was to conduct a (1) systematic review of clinical outcomes following cartilage restorative and reparative procedures in the glenohumeral joint; (2) to identify patient specific prognostic factors that predict clinical outcome after cartilage surgery of the shoulder; (3) to provide treatment recommendations based on the best currently available evidence and to (4) highlight gaps in the literature that require future research

METHODS:

We searched MEDLINE (1948 to February Week 1 2012) and EMBASE (1980 to 2012 Week 5) for studies evaluating the results of arthroscopic debridement, microfracture, osteochondral autograft or allograft transplants and autologous chondrocyte implantation for focal and diffuse glenohumeral chondral lesions. Other inclusion criteria included minimum 1year follow-up. The Oxford Level of Evidence Guidelines and GRADE recommendations were used to rate the quality of available evidence and to make treatment recommendations.

RESULTS

Twelve articles met our inclusion criteria which resulted in a total of 315 patients. Six of these articles pertained to arthroscopic debridement for diffuse glenohumeral arthritis (n=249), 3 to microfracture (n=47), 2 to osteochondral autograft transplantation (n=15) and 1 to autologous chondrocyte implantation (ACI) (n=5). While most studies reported favorable results for the reported procedures, sample heterogeneity and differences in the use of functional and radiographic outcome measures precluded a meta-analysis. Several positive and negative prognostic factors were identified across. Given that all of the eligible studies were observational retrospective case series without control groups, the quality of evidence available for the use of the aforementioned procedures is considered “very low” and “any estimate of effect is very uncertain.”

CONCLUSION:

More research is necessary to determine which treatment for focal and large chondral pathology in the shoulder provides the best long-term outcomes. We encourage high-volume centers to establish the necessary alliances to conduct the blinded, randomized clinical trials and prospective comparative cohort studies necessary to rigorously determine which treatments result in the most optimal outcomes. At the present time, high quality evidence is lacking to make strong recommendations and decision-making in this difficult patient population is thus, made on a case-by-case basis.

INTRODUCTION

While much has been written regarding the treatment of chondral lesions in the knee,¹ until recently glenohumeral articular cartilage lesions have remained a poorly understood and usually incidentally diagnosed entity.²⁻⁶ However, increased awareness, and the widespread use of magnetic resonance imaging⁷⁻¹¹ and arthroscopy has allowed for a more conscientious and thorough evaluation of the articular surfaces¹² which in turn has demonstrated that chondral defects in the shoulder are more common than previously thought. While the incidence of glenohumeral articular cartilage lesions in the general population is unknown, arthroscopies performed for other indications reveal an incidence rate of 6-17%.^{3,13,14} After an anterior instability event, these lesions are even more common at 23% of the glenoid side and 8% on the humeral side.

Numerous factors may incite a chondral lesion, including trauma, instability, previous surgical intervention with associated chondrolysis, osteonecrosis, rotator cuff arthropathy, septic arthritis, inflammatory arthritis, osteoarthritis, and osteochondritis dissecans. Chondral lesions are generally identified in association with other intra-articular glenohumeral pathology.²⁻⁶ For instance, the presence of a superior labral anterior-posterior tear increases the likelihood of identification of a chondral lesions from 4 to 20% on the humeral side and 5 to 18% on the glenoid side.^{15,16} In young patients, the glenohumeral pathology most commonly leading to the discovery of chondral lesion is instability.²⁻⁶ A dislocation event increases the risk of the development of glenohumeral osteoarthritis 10-20 times¹⁷ and the incidence of glenohumeral osteoarthritis is 10-20% in those that suffer an instability event at mid- to long-term follow-up.¹⁸

While the natural history of these chondral lesions is largely unknown, they may progress to glenohumeral osteoarthritis.²⁻⁶ While rare¹⁹ glenohumeral osteoarthritis can have significant effects on a patient's global function, with declines in health-related quality of life on-par with diabetes and coronary artery disease.^{20,21}

The factors that lead to progression are largely unknown and possibly different from those within the knee given that the glenohumeral joint is not a classic weight-bearing joint in the same sense that the lower extremity diarthrodial joints experience load. Shear stresses related to physiologic glenohumeral translation may contribute to progression. In comparison to the knee, the articular cartilage of the humeral head and glenoid fossa are thin at 1.24 and 1.88 mm thick respectively, which leaves less margin before exposure of the subchondral bone.²² It should be noted that this margin is even thinner at the periphery of the humeral head and at the center of the glenoid fossa. Systematic chondral degenerative changes related to age likely also contribute to progression, as do osseous lesions leading to articular incongruity.¹⁸ Finally, chondral defects of the glenohumeral joint are generally very well tolerated and often asymptomatic, thus it is incumbent upon the evaluating physician to properly determine and treat other more common sources of shoulder pain prior to embarking on cartilage-specific treatment.

Once a symptomatic chondral lesion has been identified, a trial of non-operative therapy is warranted, including ice, nonsteroidal anti-inflammatory medications, and physical therapy. Therapy with a focus on strengthening of the periscapular musculature and rotator cuff may be particularly effective to address any concomitant scapular dyskinesis. In addition, in overhead throwers stretching can be useful to address any glenohumeral internal rotation deficit that may be contributing to microinstability and may be placing abnormal stress upon the articular cartilage and therefore possibly contributing to progression. We also make use of intraarticular corticosteroid injections in patients with an inflammatory component to their discomfort. Hyaluronic acid injection may also be used, although its use in glenohumeral lesions remains off-label.²³ The efficacy of non-operative treatment protocols in the short and long-term in regards to symptomatic management and alteration of natural history remains to be determined.

In patients who have tried a comprehensive course of non-operative treatment with residual discomfort, operative treatment can be considered. A variety of operative treatment options exist for these lesions. These options can generally be classified into reparative, restorative, and salvage treatments. Reparative options include microfracture techniques.^{2, 24-27} Restorative options include cellular-based techniques such as autologous chondrocyte implantation,²⁸ osteochondral autograft transplantation,²⁹ and osteochondral allograft transplantation.³⁰ Salvage techniques include debridement techniques with or without capsular release, chondroplasty,^{3, 31-36} and subacromial decompression;³⁷ biological resurfacing techniques with meniscal allograft, anterior capsule, periosteum, or another biologic interposition material;³⁸⁻⁴² and prosthetic resurfacing and arthroplasty techniques. While total shoulder arthroplasty generally provides excellent pain relief and function, the limited lifespan of prosthetic replacements limits application in younger patients and thus our review is limited to non-arthroplasty techniques.^{43, 44}

Given the plethora of treatment options, the treating surgeon who encounters a chondral defect is left without clear guidelines of which option might provide their patient with the best outcome. While several reviews have been written,²⁻⁶ no inclusive, recent systematic reviews exist within the literature to provide the surgeon with evidence-based recommendations for treatment of these lesions. In addition, the majority of the evidence on the subject has been released within the past two years, which may make prior conclusions less pertinent today.

The objective of this study was to conduct a (1) systematic review of clinical outcomes following cartilage restorative and reparative procedures in the glenohumeral joint; (2) to identify patient specific prognostic factors that predict clinical outcome after cartilage surgery of the shoulder; (3) to provide treatment recommendations based on the best currently available evidence and to (4) highlight gaps in the literature that require future research.

METHODS

Literature Search

We searched MEDLINE (1948 to February Week 1 2012) and EMBASE (1980 to 2012 Week 5) using the following key words: (glenohumeral OR shoulder) AND (cartilage OR osteochondral OR arthritis OR degenerative) AND (arthroscop* OR debridement OR osteochondral OR microfracture OR autologous OR implantation). Search terms were broad as to encompass all possibilities for applicable studies. All review articles were then manually cross-referenced to make certain no relevant studies were missed.

Inclusion criteria were (1) studies that reported on clinical outcomes following non-arthroplasty treatment for the spectrum of chondral lesions of the glenohumeral joint including focal and diffuse articular disease on the humerus and/or glenoid; (2) patients greater than the age of 16 years; and (3) minimum 6 months follow-up. We excluded (1) technique articles; (2) case reports; (3) review articles; and (4) articles which discussed biological resurfacing of the glenohumeral joint due to a recently published comprehensive systematic review on this topic.⁴⁵

Data Abstraction

The data from each study that met the inclusion criteria was abstracted by one reviewer (CG) and verified by another (JC). Study data which was determined to be of interest *a priori* included the type of treatment, year of publication, study period, type of clinical study, inclusion/exclusion criteria, number of patients enrolled, number of patients available for follow-up, age, minimum follow-up, length of follow-up, proportion of dominant extremities involved, gender, concomitant procedures, number of workman's compensation patients, classification of pre-operative arthritis, post-operative rehabilitation, and statistical analysis used. Preoperative and postoperative data of interest was range of motion, patient satisfaction, clinical outcome scores, and the amount of people that ultimately failed treatment (requiring resurfacing or arthroplasty) was also recorded. Functional outcomes that were of interest included the University of California, Los Angeles (UCLA) outcome score,⁴⁶ Constant-Murley outcome score,⁴⁷ American Shoulder and Elbow Surgeons (ASES) outcome score,⁴⁸ Simple Shoulder Test (SST),⁴⁹ visual analogue scale (VAS) for pain, and overall patient satisfaction rates. The presence of bias was determined and analyzed for each eligible study. Finally, the level of evidence (I-IV) of each included study was determined according to the Oxford Level of Evidence Guidelines.⁵⁰

Statistical analysis

While weighted averages and results of combined dichotomous variables were used when applicable, a comparison of weighted means could not be performed with statistical integrity. A majority of these studies reported their results as an average without a standard deviation. Additionally, while some studies used validated outcome scores, others used subjective personal assessments based off of the clinician's own functional and pain scores. A meta-analysis was unable to be performed.

RESULTS

We obtained 774 articles from Medline and 730 articles from EMBASE for a total of 1504 articles. Once duplicate articles were manually removed, 894 unique articles remained from the combined pool of Medline and Embase. Duplicates were confirmed with the use of EndNote bibliographic software (Thomson Reuters, Carlsbad, CA). Of these articles, we screened the articles by article title relevance and were left with 56 studies. These articles were then further screened to remove case reports, technique reports, and reviews by reviewing their abstracts. The full manuscripts of thirteen studies were reviewed to ensure that they met our inclusion criteria. One was removed due to a follow-up period of 3 months and a patient age of 13 years.⁴¹ Two authors then independently reviewed 12 articles which met the inclusion criteria. Six of these articles pertained to arthroscopic debridement for diffuse glenohumeral arthritis, 2 to microfracture, 1 to microfracture plus periosteal flap transfer, 2 to osteochondral autograft transplantation (OATS), and 1 to autologous chondrocyte implantation (ACI). Within the microfracture studies, associated pathologies included subacromial bursitis, subacromial impingement, biceps tendonitis, superior labral anterior posterior tears, acromioclavicular degenerative joint disease, and glenohumeral instability.^{24, 25, 35}

General Characteristics of Included Studies

The general characteristics of included studies are highlighted in Table 1. All of the eligible studies were unblinded prospective²⁶ or retrospective^{12, 24-26, 29, 31, 32, 35, 36, 51-53} case series without comparative control groups. The level of evidence assigned to each study was IV. The patient populations in each subgroup of treatment options are pooled and presented below separately where appropriate.

Operative Procedures

Overall, there were 315 shoulders at final follow-up across all 12 included studies. Of these, six studies involved arthroscopic debridement (n=249), 2 involved microfracture (n= 42), 1 involved microfracture and periosteal flap transfer (n=5), 2 involved OATS (n=15, though 7 of these are the same patients at two different times), and 1 involved ACI (n=5).

Demographics

All studies provided data regarding mean patient age and patient sex with the exception of one study.⁵³ Only three studies provided data regarding involvement of the dominant extremity.^{12, 24, 31} Concomitant surgeries were reported in all the microfracture patients and all but one of the arthroscopic debridement studies;³⁶ they occur rarely in the other studies.^{26, 29, 51, 52} The debridement and microfracture procedure were all performed arthroscopically,^{12, 24, 25, 31, 32, 35, 36, 53} whereas patients that underwent OATS, periosteal transfer, and ACI had to undergo an additional open procedure.

Combining data from the arthroscopic debridement studies resulted in a total of 249 patients. Their mean weighted age was 46.8 (range 16-77). For the studies that reported gender, 130 patients were men (67.0%) and 64 were women (33.0%). The dominant extremity was involved 59.9% of the time. While insufficient data is available in the source studies to specify the mean lesion size or extent, authors reported upon the use of this technique for both mild and severe disease.^{12, 31, 32, 35, 36}

Of the studies that reported concomitant procedures, 142 out of 223 (63.7%) of patients had other procedures performed at the same time. The most common procedures were subacromial decompression, acromioplasty, capsular releases and biceps tenodesis. Average follow-up time was 30.2 months.

Among the 47 patients that underwent microfracture, the mean weighted age was 41.7 (range 18-59). Thirty-three patients (75%) were male. Average follow up time was 37.4 months. Only Frank and colleagues listed concomitant procedures, which were performed in 64.7% of cases and included capsular release (12%), subacromial decompression (47%), biceps tenodesis (24%), distal clavicular resection (6%) and loose body removal (6%). They also reported that the dominant upper extremity was involved in 52.9% of cases.²⁴

Data from the OATS studies cannot be pooled since they represent the same patients at two different periods in time and therefore can only have their functional outcomes studied. Additionally, weighted age means and other pooled data cannot be collected from the ACI and microfracture and periosteal flap transfer because they each have one representative study that fits the inclusion criteria.

Wear characteristics

Each study had its own inclusion criteria as to what they deemed as needing an operation. More of the recent studies use the Outerbridge classification.⁵⁴ Kerr and McCarty looked at the functional and pain differences in patients with Outerbridge II/ III versus IV stage as well as unipolar versus bipolar lesions.³¹ Cameron *et al.* compared the differences between lesions greater than or less than 2cm² as well as location of each lesion.³¹ While Ogilvie-Harris and colleagues did not overtly use the Outerbridge classification, their descriptions of mild and severe arthritis are comparable to Outerbridge II/ III and IV, respectively. Weinstein and colleagues only reported on patients with Outerbridge II or III lesions.³⁶ The remaining studies had inclusion criteria of requiring a full-thickness cartilage lesion on the humeral head, glenoid, or both sides. Only two studies looked at patients with a minimum size requirement for cartilage lesions (>100mm²).^{29, 52}

Functional scores and outcome measures

Four of the six arthroscopic debridement articles report on their own subjective outcome measures in terms of function, pain, and satisfactory result.^{12, 31, 36, 53} The remaining studies have a validated outcome measure^{24, 26, 29, 32, 33, 35, 51, 52}. These outcome measures include the WOOS score, Marx Activity Level, Constant, ASES, SANE, SST, SF-12, VAS, and UCLA score.^{31, 35} Kerr reported that the mean WOOS, ASES, and SANE score was .64 (range, .12-.98), 12.6 (range, 9.0-18.0), and 71% respectively. Cameron et al showed pain relief in 88% of their patients with the average time to pain relief being 5 weeks after surgery.³¹ The mean duration of pain relief was 28 months. Functional scores also significantly improved from a pre-operative level. 87% of the total number of patients also noted improvement in their shoulders after surgery. In mild arthritic shoulders, Ogilvie-Harris et al reveal that 66% of these patient experienced satisfactory outcomes.⁵³ With regard to ASES and SST, Van Thiel et al reported a significant increase in preoperative values as well as a significantly lower VAS score.³⁵ Weinstein showed excellent or good results in 80% of the study's patients.³⁶

Microfracture has also been shown to be an effective surgical treatment for isolated full-thickness cartilage defects. Patients undergoing microfracture had overwhelming positive outcomes.^{24, 25} Frank, et al report a significant decrease in VAS (5.6 ± 1.7 to 1.9 ± 1.4) after surgery.²⁴ Their SST improved from 5.7 ± 2.1 to 10.3 ± 1.3 with 92.3% of patients stating that they would get the surgery again. Similar results were reported by Millet et al²⁵. Their patients had significant reductions in pain with improvements in ASES score (from 60 to 80). Of those patients that participated in sports, all patients reported their ability to compete improved significantly. Siebold et al reported functional and pain improvements in patients treated with microfracture and periosteal flap.²⁶ The Constant score significantly improved over the preoperative level (from 43.4% to 81.8%). Pain was also reduced significantly to 18.6 points.

All patients that underwent an OATS procedure at 9 year follow-up were satisfied with the results.⁵² The mean Constant score improve from 76.2 preoperatively to 90.0 post-operatively. This score reflects improvements in both pain and function. After ACI, 3 out of the four patients were satisfied with the results though all had good to excellent outcomes as reflected in the Constant score.⁵¹

Constant scores (unadjusted for age and sex) were reviewed only in the patients with microfracture and periosteal flap, OATS, and ACI.^{26, 29, 51, 52} While the weighted average pre-operative Constant scores in those groups were dissimilar, their post-operative Constant scores were similar. Statistical significance could not be determined based on the data presented in the papers due to the lack of distribution characteristics. The weighted-mean pre-operative Constant scores for the microfracture and periosteal flap, OATS, and ACI procedure is 67.1. The weighted mean post-operative Constant scores is 87.0.

Unfortunately, given the wide array of shoulder outcomes measured as well as the heterogenous patient populations across included studies, outcomes could not be pooled in a statistically reliable manner.

Prognostic Factors

Of the patients undergoing arthroscopic debridement, all studies found no correlation between age and gender with functional or pain outcomes. Kerr and McCarty noted that among patients treated with debridement, unipolar lesions statistically fair better than bipolar lesions with respect to SANE score, Marx Activity Level, WOOS, and ASES scores.³² This study found that regardless the size of the osteochondral lesion, each patient had similar improvements in all their outcome measures. On the other hand, lesions greater than 2 cm² were reported by Cameron et al to be a negative prognostic factor in regards to time with pain relief and failure following debridement.³¹ They did not find any correlation between pre-operative pain and the size of lesion or radiographic appearance of the glenohumeral joint.³¹ While lesions that were bipolar tended to have worse outcomes, there was no statistical significance. Ogilvie-Harris and Wiley reported that patients that had “mild” arthritis had a 66% chance of having a satisfactory outcome following debridement, though the group did not report if this was statistically significant.⁵³ Both Weinstein and colleagues and VanThiel and colleagues reported that there was no correlation between arthritic grade, radiographically or arthroscopically, and outcomes.^{35,36} Van Thiel et al did note that all 16 patients which eventually underwent arthroplasty had grade 4 articular changes, with the majority with bipolar lesions.³⁵

Patients that underwent microfracture did not have outcomes affected by either their gender or age. Frank and colleagues saw improvements in patients with all varied sizes and locations of lesions; the group did not compare groups of different location or sizes.²⁴ The group did note however, that less pain was reported in follow-up patients that underwent physical examination and surveys compared to the survey group alone. Millet and colleagues found that isolated osteochondral defects of the humerus had better outcomes.²⁵ Prior surgery was considered a negative prognostic indicator. While there was a negative correlation between the size of lesions and ASES score, though the results were not significant. However, pain scores shows a statistically significant correlation with lesion size, with larger lesions faring worse.²⁵

No prognostic factors could be garnered from microfracture and flap, OATS, or ACI study since their number treated was too small to perform an adequately powered statistical analysis.

Failure Rate

A treatment failure in this systematic review was defined as a patient that needed to undergo resurfacing (biologic or with hardware) or arthroplasty. Failure rates in the arthroscopic debridement studies were generally well-reported. Of note, some studies such as Van Thiel and colleagues excluded patients that underwent arthroplasty from their outcome scores and statistical analysis. Of the studies examining debridement that reported failure rates,^{31,32,35} there were 26 reported failures (14.7%). The patients that underwent microfracture had a failure rate of 10.6% (n=5 failures). The other treatment modalities had a limited number treated and did not report any failures.

Of the patients that eventually failed arthroscopic debridement, the mean time to their arthroplasty, resurfacing, or allograft was 13.7 months. The mean time to arthroplasty in the microfracture group was 28.4 months.

DISCUSSION

Assigning Level of Evidence and Providing Evidence Based Treatment Recommendations

The guidelines put forth by the Grading of Recommendations Assessment, Development and Evaluation (GRADE) Working Group⁵⁰ were used to determine the quality of available evidence and strength of recommendation for the cartilage therapies of interest in this review (Table 5). Based upon this system, the best study design available for all interventions was observational case series without comparative controls groups. While several studies reported important and validated outcomes (Simple shoulder test, Constant-Murley scores, American Shoulder and Elbow Surgeons scores, etc.) several other studies reported non-validated, subjective, and study-specific outcome assessment tools (ex. Excellent, good, fair, poor). There are serious limitations in study quality, mostly related to retrospective design, short follow-up, sample heterogeneity, and limited cohort sizes. There are important inconsistencies in the prognostic factors identified between studies, specifically with respect to whether lesion size and grade of arthritis affects the ability of debridement or microfracture to provide symptomatic benefit for focal and diffuse chondral lesions, respectively. There is also some uncertainty about the internal validity of the studies, mostly due to the inclusion of concomitant procedures and the use of non-validated outcome measures by some authors. Data is both imprecise and sparse, and the probability of reporting bias is high. Therefore, the quality of evidence available for the use of debridement, microfracture, osteochondral autogenous transplantation, and autologous chondrocyte implantation in the treatment of glenohumeral chondral lesions is considered “very low” using this system. Using the GRADE system, these determinations suggest, “any estimate of effect is very uncertain”⁵⁰ – i.e. that our understanding of the proper surgical treatment of these lesions will likely be considerably altered by higher quality studies. In addition, because of the lack of high quality of evidence the balance of benefit and harms, as well as the societal balance of net benefits and net costs cannot be determined.

Summary of results

Despite significant limitations in study design, the majority of studies included showed overall good results. When defined as need for subsequent biologic resurfacing or prosthetic arthroplasty, failure rates were low at 14.7% for debridement (diffuse lesions) and 10.6% for microfracture (focal lesions) at a mean of 13.7 and 28.4 months respectively. It is possible that with longer follow-up these rates might be increased. While statistical significance could not be determined, when debridement, microfracture, and OATS outcomes were combined, weighted-mean Constant scores for studies that used this outcome measure improved from 67.1 pre-operatively to 87.0 at the time of final follow-up. Because the minimum clinically important difference in Constant score with respect to glenohumeral chondral lesions has not yet been determined, the clinical importance of this finding is uncertain. In addition, satisfaction rates were

high with all procedures (66-100%).^{12, 25, 29, 36, 51-53} Notably, that satisfaction rates were high, does not equate with a conclusion that all of these procedures perform equally well. There is considerable selection bias for a specific procedure chosen to manage a symptomatic cartilage defect based upon published suggested guidelines and algorithms. (Ref our articles for treatment algorithm of non arthroplasty tx of GH arthritis)

Several studies reported prognostic factors that could be used to counsel patients pre-operatively (Table 4). Positive prognostic factors include lesion less than two cm in size,^{25, 31} unipolar lesions,³² less advanced lesions,⁵³ isolated lesions of the humerus.²⁵ Negative prognostic factors include lesions larger than two cm in size,^{25, 31} bipolar lesions,³² and prior surgical intervention.²⁵ However, several other studies were unable to demonstrate any correlation between either the arthroscopic or radiographic grade of cartilage degeneration, suggesting that patients with advanced disease may also be well-served with arthroscopic debridement.^{24, 31, 35, 36} Similarly, other studies were also unable to demonstrate any connection between lesion size and prognosis of improvement with surgical intervention.^{24, 32}

Past reviews have suggested algorithms to guide the operative treatment of glenohumeral articular cartilage lesions.^{2, 3, 5} These algorithms have suggested that factors to guide treatment should include (1) whether the lesion was encountered incidentally, in which case only arthroscopic debridement should be considered;^{2, 5} (2) whether the lesion is bipolar, in which case biological resurfacing should be considered;^{2, 5} (3) whether the lesion involves bone loss in which case an osteoarticular graft or resurfacing prosthesis should be considered;^{3, 5} (4) whether the lesion is small, in which case microfracture and osteoarticular autografting could be considered;^{2, 3, 5} and (5) whether the lesion is large, in which case autologous chondrocyte implantation or osteoarticular allografting could be considered.^{2, 3, 5} Reviewing the literature in a systematic fashion allows us to evaluate these five principles of treatment. Overall, the evidence does suggest that bipolar lesions (2) and larger lesions (5) may be more likely to fail with microfracture and debridement and thus more alternatives should be considered – however no evidence exists to suggest that the alternatives previous reviews have proposed (autologous chondrocyte implantation and osteoarticular allografting) have better outcomes for these lesions.^{2, 3, 5} Further research will be needed to evaluate these principles and to delineate refined treatment recommendations.

A number of limitations exist with our study. (1) The quality of our recommendations and the quality of our conclusions are limited by the quality of the original data from which these recommendations are drawn. No randomized clinical trials or prospective/retrospective cohort studies with comparative controls have been conducted to date to evaluate any of surgical techniques used in the treatment of glenohumeral chondral defects. The highest quality evidence produced to date is level IV, and thus our conclusions are subject to considerable bias and the interpretation of our results is necessarily limited. (2) Our exclusion criteria may have eliminated evidence that could have altered our conclusions, in particular limitation to studies in the English language may bias towards research performed in the United States and Europe to the exclusion of the rest of the world. (3) Our study design compares retrospective case series performed by different

authors. Significant heterogeneity exists within these studies, with respect to pre-operative evaluation, operative protocol, post-operative rehabilitation, etc. The diversity between the studies from which our data is drawn limits our ability to aggregate their results into meaningful conclusions. (4) Only published data is included in this trial, and thus our conclusions must be interpreted in light of the publication bias. In clinical practice these procedures may be less efficacious than it would appear in this review because less successful results might be less likely to be published.

Future directions

A randomized clinical trial could more adequately determine treatment superiority of technique over another. However, given the overall rarity of these procedures even in high-volume referral centers, such a trial may never be conducted without collaboration between centers. Alternatively, it may be feasible to perform multi-center studies with comparative control groups that are conducted in a prospective manner such that pertinent baseline variables are concomitantly documented and followed. We encourage high-volume centers to establish the necessary alliances to conduct the randomized clinical trials and prospective comparative cohort studies necessary to rigorously determine whether debridement, microfracture, cellular-based techniques, osteochondral autografting, osteochondral allografting, or prosthetic resurfacing provides patients with articular cartilage lesions of the glenohumeral joint with the optimal outcome. Each of these techniques may have a role depending upon patient characteristics, such as age, lesion location, associated bone loss, and lesion size and thus stratification and subgroup analysis may be important aspects of these trials.

Conclusions

A variety of options exist for the treatment of articular cartilage defects of the glenohumeral joint. For diffuse outerbridge stage II and III lesions arthroscopic debridement and chondroplasty reliably provides good outcomes although the degree of pain relief and functional return may be incomplete and relatively short-lived. More research is necessary to determine which restorative technique, microfracture, cellular based techniques, osteochondral autografting, or osteochondral allografting, provides the best long-term function for focal chondral lesions. High quality evidence is lacking to make strong recommendations.

Figures

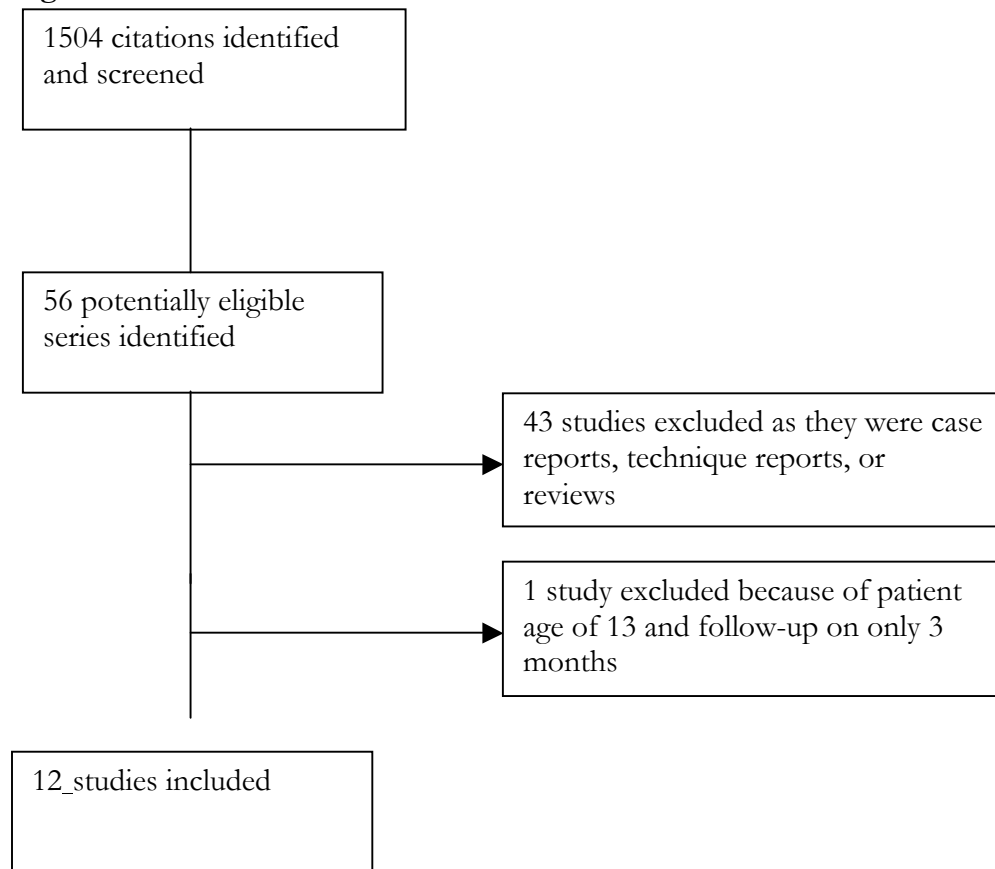


Figure 1. Consolidated Standards of Reporting Trials (CONSORT) flowchart shows the effect of exclusion criteria on the number of included studies. Initial literature searches revealed 56 citations, 12 ultimately were included.

Tables

Author	Technique	Type of Study	Level of Evidence	Shoulders @ final f/u	Effective f/u (%)	f/u length [months (range)]	Bias
Cameron ³¹	Debridement	RCS	IV	61	87.1%	34 (12-79)	Selection
Ellman ¹²	Debridement	RCS	IV	10	55.5%	n/a (6- 18)	Selection
Kerr ³²	Debridement	RCS	IV	20	100%	20 (12-33)	Selection
Ogilvie-Harris ⁵³	Debridement	RCS	IV	54	100%	36	Selection
VanThiel ³⁵	Debridement	RCS	IV	71	88%	47 (18-77)	Selection
Weinstein ³⁶	Debridement	RCS	IV	25	100%	34 (12-63)	Selection
Frank ²⁴	Microfracture	RCS	IV	17	88.2%	27.8 (12-89)	Selection
Millet ²⁵	Microfracture	RCS	IV	25	100%	34 (12-63)	Selection
Siebold ²⁶	Microfracture +periosteal flap	PCS	IV	5	100%	25.8 (24-31)	Selection
Scheibel ²⁹	OATS	RCS	IV	8	100%	32.6 (8-47)	Selection
Kircher ⁵²	OATS	RCS	IV	7	100%	105 (91-117.6)	Selection
Buchmann ⁵¹	ACT-Cs	RCS	IV	4	100%	41.3 (11- 71)	Selection

Table 1: Characteristics of included studies. RCS= retrospective case series; PCS = Prospective Case Series; OATS= osteochondral autologous transplantation; ACT-Cs= autologous chondrocyte transplantation—collagen membrane seeding; f/u= follow-up,

Author	Age [years (range)]	Gender [n(%male)]	Dominant Extremity [n(%)]	Concomitant Procedures[n(%)]	Open vs. Arthroscopic	Post-op Rehab
Arthroscopic Debridement						
Cameron ³¹	49.5 (21-73)	41 (67.2%)	29 (47.5%)	29 (47.5%)	Arthroscopic	
Ellman ¹²	n/a	11 (61.1%)	8 (44%)	15 (83.3%)	Arthroscopic	
Kerr ³²	38 (20-54)	12 (63.2%)	n/a	16 (84.2%)	Arthroscopic	Sling, PROM 1st day, AROM when pain allowed (except SLAP repair which was 6 weeks)
Ogilvie-Harris ⁵³	n/a	n/a	n/a	27 (50.0%)	Arthroscopic	
VanThiel ³⁵	47 (18-77)	47 (66.2%)	n/a	55 (77.5%)	Arthroscopic	
Weinstein ³⁶	46 (27-42)	19 (76.0%)	n/a	n/a	Arthroscopic	Sling, PROM 1st day, AROM as tolerated. Return to activities within 4-6wks
Microfracture						
Frank ²⁴	37 (18-55)	7 (53.8%)	9 (52.9%)	11 (64.7%)	Arthroscopic	Sling 2-4wks PROM immediately, unrestricted strength at 12 weeks, 16 weeks unrestricted activity, 6mos overhead activity.
Millet ²⁵	43 (19-59)	25 (83.3%)	n/a	25 (100%)	Arthroscopic	
Microfracture and periosteal flap						
Siebold ²⁶	32 (16-56)	3 (60%)	n/a	0	Arthroscopic and open	Sling 48hrs, abduction pillow 3 weeks, PROM 3rd day, 4-6wks AROM, then unrestricted activity
OATS						
Scheibel ²⁹	43.1 (23-57)	6 (75%)	n/a	0	Arthroscopic and open	Sling, 3 wks abduction pillow, PROM on post-op day 3, no ER until 6wks, 4-6wks AROM, strengthening
Kircher ⁵²	n/a	6 (85.7%)	n/a	0	Arthroscopic and open	
ACI						
Buchmann ⁵¹	29.3 (21-36)	4 (100%)	n/a	0	Arthroscopic	

					and open	
--	--	--	--	--	----------	--

Table 2: Patient demographics. PROM= passive range of motion; AROM= active range of motion, SLAP= superior labral tear from anterior to posterior; ER= external rotation.

Author	Outcomes Measure	Pre-op Value [mean (range)]	Post-op Value [mean (range)]	Outcome Measure II	Pre-op Value [mean (range)]	Postop Value [mean (range)]	Preop VAS* [mean (range)]	Postop VAS [mean (range)]	Satisfaction [n (%)]	Resurfacing/ Arthroplasty [n(%)]
Arthroscopic Debridement										
Cameron ³¹	Self-assessment (functional)	24 ± 1.9 ⁺	38.7 ± 1.9 ⁺	Improvement		87% noted improvement	5 (at rest)	1.9 (at rest)	6.28/10	6 (9.8%)
Ellman ¹²	Satisfaction	n/a	n/a	n/a	n/a	n/a	n/a	n/a	9 (90%)	0
Kerr ³²	WOOS	n/a	.63 (.12- .98)	ASES		75.3 (24-100)	n/a	n/a	n/a	3(15.0%)
Ogilvie-Harris ⁵³	n/a	n/a	n/a	n/a	n/a	n/a	n/a	n/a	G: 66%(mild); 33% (severe)	n/a
VanThiel ³⁵	ASES	51.8 (8-85)	72.7 (10-100)	SST	6.1 (0-12)	9.0 (3-12)	4.8 (1-9)	2.7 (0-9)	n/a	16 (22.0%)
Weinstein ³⁶	Pain relief		76%	Good/excellent		80%	n/a	n/a	92%	1 (4.0%)
Microfracture										
Frank ²⁴	ASES	44.3 ± 15.3	86.3 ± 10.5	SST	5.7 ± 2.1	10.3 ± 1.3	5.6 ± 1.7	1.9 ± 1.4	n/a	2 (14.3%)
Millet ²⁵	ASES	60 (20-80)	80 (45-100)	Painless use	22%	55%	3.8 (0-7)	1.6 (0-	9.5 /10	3 (9.7%)

				of arm above neck				5)		
Microfracture and periosteal flap										
Siebold ²⁶	Constant	43.4	81.8	n/a	n/a	n/a	n/a	n/a	n/a	0
OATS										
Scheibel ²⁹	Constant	73.9 (57-89.6)	88.7 (82.4-95.4)	Good/excellent		87.5%			7 (87.5%)	0
Kircher ⁵²	Constant	76.2 (65.9-89.6)	90.9 (80-97)	Good/excellent		100%			7 (100%)	0
ACI										
Buchmann ⁵¹	Constant		83.3	ASES		95.33		.25 (0-1)	100%	0

Table 3: Outcomes following various treatment modalities for cartilage lesions. WOOS= Western Ontario Osteoarthritis Score, SST = Simple Shoulder Test, ASES = American Shoulder and Elbow Surgeons, UCLA = University of California-Los Angeles, += subjective functional scale out of 60 points; ^ = * = Visual Analogue Scale using 0-10 scale with 0 being no pain and 10 being severe pain, G= good results, G/E= good/excellent results; S/VVS = satisfied and very satisfied.

Author	Prognostic Factors		
	Positive	Negative	Null*
Arthroscopic Debridement			
Cameron ³¹	Lesions <2cm	Lesions >2cm	Pre-operative pain and lesion size, radiographic grade of joint; bipolar lesions
Ellman ¹²	n/a	n/a	

Kerr ³²	Unipolar lesions	Bipolar lesions	Size of lesion
Ogilvie-Harris ⁵³	Mild arthritis		
VanThiel ³⁵	n/a	n/a	Arthroscopic or radiographic grade
Weinstein ³⁶	n/a	n/a	Arthroscopic or radiographic grade
Microfracture			
Frank ²⁴	Patients who had both physical and surveys	n/a	Lesion size, arthritic grade
Millet ²⁵	Isolated lesions of humerus	Prior surgery, size of lesion	
Microfracture and periosteal flap			
Siebold ²⁶	n/a	n/a	n/a
OATS			
Scheibel ²⁹	n/a	n/a	n/a
Kircher ⁵²	n/a	n/a	n/a
Buchmann ⁵¹	n/a	n/a	n/a

Table 4. Prognostic factors. *includes age and gender.

Recommendations	Quality assessment					Summary of fundings		
	Design	Quality	Consistency	Directness	Other modifying factors	Number of patients	Effect	Quality ⁵⁰
Arthroscopic debridement	Observational case series without comparative control groups	Serious limitations	Some important inconsistencies	Some uncertainty about directness	None	249	Not applicable: meta-analysis not appropriate	Very Low
Microfracture						47		Very Low
Autogenous chondrocyte implantation/cellular based techniques						5		Very Low
Osteoarticular autograft transplantation						8		Very Low

Table 5. Recommendations for each possible surgical intervention for the treatment of glenohumeral articular cartilage lesions graded based upon level of evidence available.

References

1. Cole BJ, Pascual-Garrido C, Grumet RC. Surgical management of articular cartilage defects in the knee. *J Bone Joint Surg Am.* Jul 2009;91(7):1778-1790.
2. Cole BJ, Yanke A, Provencher MT. Nonarthroplasty alternatives for the treatment of glenohumeral arthritis. *Journal of Shoulder and Elbow Surgery.* Sep 2007;16(5):S231-S240.
3. Elser F, Braun S, Dewing CB, Millett PJ. Glenohumeral joint preservation: current options for managing articular cartilage lesions in young, active patients. *Arthroscopy : the journal of arthroscopic & related surgery : official publication of the Arthroscopy Association of North America and the International Arthroscopy Association.* Jun 2010;26(5):685-696.
4. Heidi Ruckstuhl EDdBESBV. Post-traumatic glenohumeral cartilage lesions: a systematic review. *BMC Musculoskeletal Disorders.* 2008;9:107.
5. McCarty III LP, Cole BJ. Nonarthroplasty Treatment of Glenohumeral Cartilage Lesions. *Arthroscopy: The Journal of Arthroscopic & Related Surgery.* Sep 2005;21(9):1131-1142.
6. Sinha I, Lee M, Cobiella C. Management of osteoarthritis of the glenohumeral joint. *British journal of hospital medicine (London, England : 2005).* Jun 2008;69(5):264-268.
7. Beltran J, Rosenberg ZS, Chandnani VP, Cuomo F, Beltran S, Rokito A. Glenohumeral instability: evaluation with MR arthrography. *Radiographics : a review publication of the Radiological Society of North America, Inc.* May 1997;17(3):657-673.
8. Carroll KW, Helms CA, Speer KP. Focal articular cartilage lesions of the superior humeral head: MR imaging findings in seven patients. *AJR. American journal of roentgenology.* Mar 2001;176(2):393-397.
9. Guntern DV, Pfirrmann CWA, Schmid MR, et al. Articular Cartilage Lesions of the Glenohumeral Joint: Diagnostic Effectiveness of MR Arthrography and Prevalence in Patients with Subacromial Impingement Syndrome. *Radiology.* Feb 01 2003;226(1):165-170.
10. Hayes ML, Collins MS, Morgan JA, Wenger DE, Dahm DL. Efficacy of diagnostic magnetic resonance imaging for articular cartilage lesions of the glenohumeral joint in patients with instability. *Skeletal radiology.* Dec 2010;39(12):1199-1204.
11. Lecouvet FE, Dorzée B, Dubuc JE, Berg BCV, Jamart J, Malghem J. Cartilage lesions of the glenohumeral joint: diagnostic effectiveness of multidetector spiral CT arthrography and comparison with arthroscopy. *European Radiology.* Dec 21 2006;17(7):1763-1771.
12. Ellman H, Harris E, Kay SP. Early degenerative joint disease simulating impingement syndrome: arthroscopic findings. *YJARS.* 1992;8(4):482-487.

13. Gartsman GM, Taverna E. The incidence of glenohumeral joint abnormalities associated with full-thickness, reparable rotator cuff tears. *YJARS*. Aug 1997;13(4):450-455.
14. Paley KJ, Jobe FW, Pink MM, Kvitne RS, ElAttrache NS. Arthroscopic findings in the overhand throwing athlete: evidence for posterior internal impingement of the rotator cuff. *Arthroscopy*. Jan-Feb 2000;16(1):35-40.
15. Patzer T, Lichtenberg S, Kircher J, Magosch P, Habermeyer P. Influence of SLAP lesions on chondral lesions of the glenohumeral joint. *Knee Surgery, Sports Traumatology, Arthroscopy*. Jul 2010;18(7):982-987.
16. Rose T, Hepp P, Korner J, Josten C, Lill H. Anterosuperior labrum lesions of the shoulder joint: pathogenesis, arthroscopic treatment, and results. *Knee Surgery, Sports Traumatology, Arthroscopy*. Sep 2002;10(5):316-320.
17. Marx R. Development of arthrosis following dislocation of the shoulder: A case-control study. *Journal of Shoulder and Elbow Surgery*. Mar 2002;11(1):1-5.
18. Buscayret F. Glenohumeral Arthrosis in Anterior Instability Before and After Surgical Treatment: Incidence and Contributing Factors. *The American Journal of Sports Medicine*. Jun 18 2004;32(5):1165-1172.
19. Nakagawa Y, Hyakuna K, Otani S, Hashitani M, Nakamura T. Epidemiologic study of glenohumeral osteoarthritis with plain radiography. *Journal of Shoulder and Elbow Surgery*. Oct 1999;8(6):580-584.
20. Matsen FA, Ziegler DW, DeBartolo SE. Patient self-assessment of health status and function in glenohumeral degenerative joint disease. *Journal of Shoulder and Elbow Surgery*. Aug 1995;4(5):345-351.
21. Gartsman GM, Brinker MR, Khan M, Karahan M. Self-assessment of general health status in patients with five common shoulder conditions. *Journal of Shoulder and Elbow Surgery*. May 1998;7(3):228-237.
22. Yeh LR, Kwak S, Kim YS, et al. Evaluation of articular cartilage thickness of the humeral head and the glenoid fossa by MR arthrography: anatomic correlation in cadavers. *Skeletal radiology*. Sep 1998;27(9):500-504.
23. Silverstein E, Leger R, Shea KP. The Use of Intra-articular Hylan G-F 20 in the Treatment of Symptomatic Osteoarthritis of the Shoulder: A Preliminary Study. *The American Journal of Sports Medicine*. Jul 01 2007;35(6):979-985.
24. Frank RM, Van Thiel GS, Slabaugh MA, Romeo AA, Cole BJ, Verma NN. Clinical Outcomes After Microfracture of the Glenohumeral Joint. *The American Journal of Sports Medicine*. Apr 31 2010;38(4):772-781.
25. Millett PJ, Huffard BH, Horan MP, Hawkins RJ, Steadman JR. Outcomes of Full-Thickness Articular Cartilage Injuries of the Shoulder Treated With Microfracture. *Arthroscopy: The Journal of Arthroscopic & Related Surgery*. Aug 2009;25(8):856-863.

26. Siebold R, Lichtenberg S, Habermeyer P. Combination of microfracture and periosteal-flap for the treatment of focal full thickness articular cartilage lesions of the shoulder: a prospective study. *Knee Surgery, Sports Traumatology, Arthroscopy*. Jun 2003;11(3):183-189.
27. Slabaugh MA, Frank RM, Cole BJ. Resurfacing of isolated articular cartilage defects in the glenohumeral joint with microfracture: a surgical technique & case report. *American journal of orthopedics (Belle Mead, N.J.)*. Jul 2010;39(7):326-332.
28. Romeo AA, Cole BJ, Mazzocca AD, Fox JA, Freeman KB, Joy E. Autologous chondrocyte repair of an articular defect in the humeral head. *Arthroscopy: The Journal of Arthroscopic & Related Surgery*. Oct 2002;18(8):925-929.
29. Scheibel M, Bartl C, Magosch P, Lichtenberg S, Habermeyer P. Osteochondral autologous transplantation for the treatment of full-thickness articular cartilage defects of the shoulder. *The Journal of bone and joint surgery. British volume*. Sep 2004;86(7):991-997.
30. Kropf EJ, Sekiya JK. Osteoarticular allograft transplantation for large humeral head defects in glenohumeral instability. *Arthroscopy : the journal of arthroscopic & related surgery : official publication of the Arthroscopy Association of North America and the International Arthroscopy Association*. Apr 2007;23(3):322.e321-325.
31. Cameron B. Non-prosthetic management of grade IV osteochondral lesions of the glenohumeral joint. *Journal of Shoulder and Elbow Surgery*. Mar 2002;11(1):25-32.
32. Kerr BJ, McCarty EC. Outcome of Arthroscopic Débridement is Worse for Patients With Glenohumeral Arthritis of Both Sides of the Joint. *Clinical orthopaedics and related research*. Mar 10 2008;466(3):634-638.
33. Millett PJ, Gaskill TR. Arthroscopic management of glenohumeral arthrosis: humeral osteoplasty, capsular release, and arthroscopic axillary nerve release as a joint-preserving approach. *Arthroscopy : the journal of arthroscopic & related surgery : official publication of the Arthroscopy Association of North America and the International Arthroscopy Association*. Sep 2011;27(9):1296-1303.
34. Richards DP, Burkhart SS. Arthroscopic Debridement and Capsular Release for Glenohumeral Osteoarthritis. *Arthroscopy: The Journal of Arthroscopic & Related Surgery*. Sep 2007;23(9):1019-1022.
35. Van Thiel GS, Sheehan S, Frank RM, et al. Retrospective Analysis of Arthroscopic Management of Glenohumeral Degenerative Disease. *Arthroscopy: The Journal of Arthroscopic & Related Surgery*. Nov 2010;26(11):1451-1455.
36. Weinstein DM, Bucchieri JS, Pollock RG, Flatow EL, Bigliani LU. Arthroscopic debridement of the shoulder for osteoarthritis. *Arthroscopy: The Journal of Arthroscopic & Related Surgery*. Jul 2000;16(5):471-476.
37. Guyette T. Results of arthroscopic subacromial decompression in patients with subacromial impingement and glenohumeral degenerative joint disease. *Journal of Shoulder and Elbow Surgery*. Aug 2002;11(4):299-304.

38. Beer JF, Bhatia DN, Rooyen KS, Du Toit DF. Arthroscopic debridement and biological resurfacing of the glenoid in glenohumeral arthritis. *Knee Surgery, Sports Traumatology, Arthroscopy*. Jun 18 2010;18(12):1767-1773.
39. Bhatia DN, van Rooyen KS, Du Toit DF, De Beer JF. Arthroscopic Technique of Interposition Arthroplasty of the Glenohumeral Joint. *Arthroscopy: The Journal of Arthroscopic & Related Surgery*. Jun 2006;22(5):570.e571-570.e575.
40. Krishnan SG, Nowinski RJ, Harrison D, Burkhead WZ. Humeral hemiarthroplasty with biologic resurfacing of the glenoid for glenohumeral arthritis. Two to fifteen-year outcomes. *The Journal of bone and joint surgery. American volume*. May 2007;89(4):727-734.
41. McNickle AG, L'Heureux DR, Provencher MT, Romeo AA, Cole BJ. Postsurgical Glenohumeral Arthritis in Young Adults. *The American Journal of Sports Medicine*. Sep 02 2009;37(9):1784-1791.
42. Pennington WT, Bartz BA. Arthroscopic Glenoid Resurfacing With Meniscal Allograft: A Minimally Invasive Alternative for Treating Glenohumeral Arthritis. *Arthroscopy: The Journal of Arthroscopic & Related Surgery*. Dec 2005;21(12):1517-1520.
43. Green A. Shoulder arthroplasty for advanced glenohumeral arthritis after anterior instability repair. *Journal of Shoulder and Elbow Surgery*. Nov 2001;10(6):539-545.
44. Matsoukis J, Tabib W, Guiffault P, et al. Shoulder arthroplasty in patients with a prior anterior shoulder dislocation. Results of a multicenter study. *The Journal of bone and joint surgery. American volume*. Aug 2003;85-A(8):1417-1424.
45. Namdari S, Alish H, Baldwin K, Glaser D, Kelly JD. Biological glenoid resurfacing for glenohumeral osteoarthritis: a systematic review. *J Shoulder Elbow Surg*. Oct 2011;20(7):1184-1190.
46. Amstutz HC, Sew Hoy AL, Clarke IC. UCLA anatomic total shoulder arthroplasty. *Clin Orthop Relat Res*. Mar-Apr 1981(155):7-20.
47. Constant CR, Murley AH. A clinical method of functional assessment of the shoulder. *Clin Orthop Relat Res*. Jan 1987(214):160-164.
48. Michener LA, McClure PW, Sennett BJ. American Shoulder and Elbow Surgeons Standardized Shoulder Assessment Form, patient self-report section: reliability, validity, and responsiveness. *J Shoulder Elbow Surg*. Nov-Dec 2002;11(6):587-594.
49. Matsen F, M Parsons. *Effective evaluation and the shoulder*. Philadelphia: WB Saunders; 2004.
50. Atkins D, Best D, Briss PA, et al. Grading quality of evidence and strength of recommendations. *BMJ*. Jun 19 2004;328(7454):1490.
51. Buchmann S, Salzmann GM, Glanzmann MC, Wortler K, Vogt S, Imhoff AB. Early clinical and structural results after autologous chondrocyte transplantation at the glenohumeral joint. *J Shoulder Elbow Surg*. Nov 1 2011.

52. Kircher J, Patzer T, Magosch P, Lichtenberg S, Habermeyer P. Osteochondral autologous transplantation for the treatment of full-thickness cartilage defects of the shoulder: results at nine years. *J Bone Joint Surg Br.* Apr 2009;91(4):499-503.
53. Ogilvie-Harris DJ, Wiley AM. Arthroscopic surgery of the shoulder. A general appraisal. *J Bone Joint Surg Br.* Mar 1986;68(2):201-207.
54. Outerbridge RE. The etiology of chondromalacia patellae. *J Bone Joint Surg Br.* Nov 1961;43-B:752-757.