

# HIP AND PELVIC INJECTIONS

**Geoffrey S. Van Thiel, MD/MBA<sup>1,2</sup>**  
*Assistant Clinical Instructor*

**Jaskarndip Chahal, MD, F.R.C.S.C<sup>1,2</sup>**  
*Associate Professor*

**Nathan Mall, MD<sup>1</sup>**

**Wendell Heard, MD<sup>1</sup>**

**Mark A. Jordan, BS<sup>1</sup>**

**Shane J. Nho, MD/MS<sup>1</sup>**  
*Associate Professor*

<sup>1</sup>*Rush University Medical Center*  
*Chicago, IL*

<sup>2</sup>*Rockford Orthopedic Associates*  
*Rockford, IL*

<sup>3</sup>*University of Toronto*  
*Toronto, Canada*

## **Abstract**

Hip and pelvic disorders can be both functionally limiting and non-specific. There are multiple offending etiologies that often have significant cross over with regard to their symptoms. An improved understanding and an increase in the treatment modalities have allowed physicians to better identify and treat a wide range of ailments. Furthermore, the increase and availability of ultrasound has made evaluation and diagnosis of a multitude of conditions possible in an office setting. These advances in diagnosis have been followed by improved treatment options including; femoroacetabular impingement procedures and hip arthroscopy.

However, the first line treatment for the majority of hip and pelvic conditions consists of extensive conservative management. Injections are a major part of the non-operative treatment and can be an effective diagnostic and therapeutic tool. This review describes injection techniques that can be used to treat a variety of hip and pelvic conditions, including; bursitis, gluteus medius tendinosis, piriformis syndrome, hamstring pathology, labral tears and osteoarthritis.

## **Introduction**

Hip and pelvic pathology has gained significant attention in contemporary orthopedics. The increase and availability of ultrasound has made evaluation and diagnosis of a multitude of conditions possible in an office setting. This has been coupled with the fact that advances in hip arthroscopy have increased the treatment options we are able to offer patients. This increase in recognition and treatment of potential pathologic conditions has also created a demand for new diagnostic and therapeutic options.

The following review details the use of injections for the diagnosis and treatment of a variety of hip and pelvic conditions, including; bursitis, gluteus medius tendinosis, piriformis syndrome, hamstring pathology, labral tears and osteoarthritis.

## **Bursitis**

### **Greater Trochanter Bursitis**

Trochanteric bursitis is a term used to describe lateral hip pain that is most often accompanied by tenderness to palpation overlying the lateral aspect of the hip. However, trochanteric bursitis is now recognized as a member of a group of disorders often referred to as the “greater trochanter pain syndrome (GTPS).” The reason for this; lateral hip pain can be due to multiple other causes such as tendinitis, muscle tears, trigger points, and iliotibial band disorders. Consequently, the exact etiology and pathology that is creating the patient discomfort is often difficult to discern. There is no doubt that inflammation of the bursa can be a pain generator, but we are refining our diagnostic abilities in order to more effectively treat this condition.

In primary care settings, the incidence of greater trochanteric pain is reported to be around 1.8 patients per 1000 per year<sup>1</sup>. It typically presents as chronic, persistent pain in the lateral hip and/or buttock that is exacerbated by lying on the affected side, with

prolonged standing or transitioning to a standing position, sitting with the affected leg crossed and with climbing stairs, running or other high impact activities.

There are specific physical exam criteria for trochanteric bursitis as described by Ege Rasmussen et al<sup>2</sup>, these include lateral hip pain with distinct tenderness about the greater trochanter and one of the following;

- Pain at the extreme of rotation, abduction, or adduction
- Pain on hip abduction against resistance
- Pseudoradiculopathy – pain radiating down the lateral aspect of the thigh

However, it must be kept in mind that these symptoms are also classic for GTPS and a full work-up should be completed.

Most cases of trochanteric bursitis are self-limiting and tend to resolve with conservative measures, such as nonsteroidal anti-inflammatories, ice, weight loss, physical therapy, and behavior modification that aim to improve flexibility, muscle strengthening and joint mechanics while decreasing pain. When conservative management fails, bursa or lateral hip injections with corticosteroid and local anesthetics can provide effective long-term relief in 70-85% of patients<sup>3,4</sup>.

### ***Injection Technique***

The greater trochanter is identified by palpating the lateral aspect of the proximal femur until a bony ridge is felt. The appropriate site for the injection is the point of maximal tenderness in this area. At this point of maximal tenderness a 22- or 25-gauge, one and one-half-inch needle is inserted perpendicular to the skin (Figure 1). It is possible to use a longer needle in obese patients. The needle should then be inserted directly down to bone and then withdrawn two to three millimeters before injecting. A volume of 9 ml of a local anesthetic and 1 ml of steroid can then be infused.

CPT Coding: Greater Trochanter Bursa injection-20610

### **Iliopsoas Bursitis/Tendinitis**

Iliopsoas tendinitis or bursitis is another recognized source of hip/groin pain. It is often seen in the setting of rheumatoid arthritis, acute trauma, overuse injury, or after total hip arthroplasty<sup>5-7</sup>. At presentation, patients may note pain with specific sports-related activities, such as jogging, running, or kicking. Pain can also be present with everyday activities that require hip flexion, including; putting on shoes, going up stairs, getting up from a seated position, and fast walking/jogging. This discomfort will typically radiate down the anterior thigh toward the knee and, occasionally, patients may report an audible snap or click in the hip.

Conservative management including rest and stretching is recommended as a first line treatment in all cases, but in refractory cases an anesthetic–corticosteroid injection into the tendon's adjacent bursa can be both diagnostic and therapeutic. Complete or near complete relief of the symptoms confirms the diagnosis. More importantly, this injection may provide significant relief and help the patient avoid surgical intervention. On the

other hand, failure of the injection to provide relief may indicate an alternate cause for hip pain, such as labral degeneration or tear.

### ***Iliopsoas Bursitis/Tendonitis Injection Technique***

An iliopsoas injection is performed with the patient in a supine position. The tendon can be localized using a linear (or curvilinear in larger patients) transducer placed in an oblique orientation parallel to the femoral neck. The iliopsoas tendon is found in a deep eccentric position within the posterior and medial part of the muscle belly and lies over the iliopectineal eminence. The iliopsoas bursa lies between the tendon and the anterior capsule of the hip joint: in normal states, it is collapsed and cannot be detected with ultrasound. Injection is then performed using a lateral approach at the level of the joint line (iliopectineal eminence) with a 22- or 20-gauge spinal needle (Figure 2). Location can be confirmed by viewing the distention of the bursa in real-time (Figure 3). Any combination of local anesthetic and steroid is acceptable. We prefer a mixture of 4 ml of lidocaine, 4 ml of Marcaine, and 2 ml of steroid. The only potential immediate complication is a transient femoral nerve palsy.

CPT Coding: Iliopsoas injection with ultrasound guidance-20552 for 1 or 2 muscles

### **Gluteus Medius Tendinosis**

As stated above, lateral hip pain is often referred to as “greater trochanteric pain syndrome,” which is a clinical syndrome characterized by chronic pain localized to the lateral aspect of the hip. It has traditionally been associated with trochanteric bursitis, however recent studies suggest that it actually may be more often the result of gluteus medius tendinopathy<sup>8-12</sup>.

Gluteus medius tendinopathy involves tenderness to palpation of the gluteus medius muscle over the lateral aspect of the hip. This can be initiated by falls, prolonged weightbearing, overuse, and sporting activities. The most common patient is the middle-aged woman that begins an exercise program with repetitive cardio. Initial presentation usually includes transient pain that worsens over a time period, a Trendelenburg gait, and weakness. These symptoms can even more specifically affect runners, as there is tilting of the pelvis with running.

On physical examination, it can be difficult to distinguish between trochanteric bursitis and gluteus medius tendinitis due to their proximity at the insertion site. A common way to differentiate the two is that resistance to abduction will not affect trochanteric bursitis, but can cause pain at the posterior insertion of the gluteus medius onto the trochanter.

### ***Injection Technique for Gluteus Medius Tendinopathy***

To prepare the patient for the ultrasound injection, local anesthetic can be injected into the skin under sterile conditions and the patient is placed in the lateral decubitus position. The ultrasound transducer is then positioned in an oblique coronal plane, and a 22-gauge spinal needle fixed to a 10-mL syringe filled with local anesthetic is inserted via an anterior approach in the long axis (Figure 4). Using continuous ultrasound

imaging, the needle is advanced while injecting a small amount of local anesthetic (Figure 5). This injection technique allows a deeper local anesthesia to be obtained for the comfort of the patient and gives a better image of the location of the tip of the needle. The fascia lata is traversed with the needle and the tip is positioned at the lateral part of the gluteus medius tendon at its insertion to the greater trochanter. A mixture of 4 ml of local anesthetic and 1 ml of a corticosteroid is then injected and monitored under real-time ultrasound.

CPT Coding: Gluteus Medius injection with ultrasound guidance-76942

### **Lateral Femoral Cutaneous Nerve Syndrome**

Compression of or injury to the lateral femoral cutaneous nerve is also known as Meralgia Paresthetica. It is a syndrome of paresthesia and pain in the lateral and anterolateral thigh that is most commonly seen in middle-aged individuals, but it can occur at all ages. Compression usually occurs at the inguinal ligament, and it can result from intrapelvic, extrapelvic, or mechanical causes. Intrapelvic causes include pregnancy, abdominal tumors, uterine fibroids, diverticulitis, or appendicitis. Extrapelvic etiologies are more common and include direct trauma to the nerve (commonly the result of a seat belt injury), tight garments, or belts. Mechanical factors can include prolonged sitting, standing, or repetitive flexion of the hip.

Symptoms include anterior and lateral thigh burning, tingling, and/or numbness. Standing, walking, or hip extension can exacerbate the symptoms and patients will often have an increase in discomfort when lying prone. The symptoms usually improve with sitting and are almost always unilateral. Physical examination findings include hyperesthesia over the lateral thigh and pain can be reproduced by pressure just medial to the ASIS. A positive Tinel sign can also be present directly over the nerve with percussion.

Diagnosis is based on clinical symptoms, but can be confirmed with relief following a localized injection. Conservative treatment and time will relieve the symptoms in most patients, however for those that continue to have discomfort a therapeutic injection of anesthetic and steroid can be performed.

### ***Lateral Femoral Cutaneous Nerve Injection***

A lateral femoral cutaneous nerve injection can be performed with a 22- or 25-gauge needle. A local anesthetic is placed in the skin approximately 1.5 cm caudal to the anterosuperior iliac spine just below the inguinal ligament. A deeper injection of 1-2 cm is then performed at an angle of approximately 60° to the skin with 4 mL of local anesthetic and 1 ml of steroid (Figure 6).

CPT Coding: Lateral femoral cutaneous nerve injection (anterior thigh) 64450

### ***Piriformis Syndrome***

Piriformis syndrome is increasingly recognized as a potential cause of buttock and posterior leg pain. The tight piriformis may become tender and contracted, or may cause compression of the surrounding structures including the sciatic nerve and blood vessels.

There are a multitude of conditions that would be included in the differential diagnosis of piriformis syndrome, including; sciatica, hip pain, and hamstring pathology. In fact, piriformis syndrome is more often a diagnosis of exclusion after all other potential causes have been ruled out.

The major clinical symptom is buttock pain, with or without posterior thigh pain, that is aggravated by sitting or activity. Physical examination may demonstrate tenderness to palpation at the greater sciatic notch or over the piriformis muscle belly. Diagnostic tests such as MRI, CT, and EMG are used to rule out other sources of pathology, unfortunately, there is no classic diagnostic test for piriformis syndrome.

Initial treatment for piriformis syndrome is always conservative, and patients will respond well to stretching techniques. The stretching will relax a tight piriformis and help to relieve any associated nerve compression. Stretches can be done in both the standing and supine positions, and involve hip and knee flexion, hip adduction, and internal rotation of the thigh. However, there are patients that fail these stretching techniques and are then good candidates for a therapeutic injection.

There are multiple different techniques and injections available. The injections include; local anesthetic, corticosteroid, botulinum toxin or any combination. Lidocaine and corticosteroid have been shown in a large study to provide symptomatic improvement when combined with physical therapy.<sup>13</sup> Botulinum toxin has also received significant attention recently in the treatment of piriformis syndrome and has been shown to be effective<sup>14</sup>. One large study compared Botox to steroid and found that Botox provided a higher degree of pain relief at 60 days<sup>15</sup>. Regardless, both steroid and Botox have been shown to provide relief when combined with physical therapy.

A variety of techniques have been described utilizing EMG, fluoroscopy, ultrasound and CT. Our preferred technique is to either use fluoroscopy or ultrasound, the technique is described in the following section.

### ***Piriformis Injection Technique***

#### **Ultrasonographic guidance**

Place a curvilinear probe horizontally between the greater tuberosity and the ischial tuberosity (Figure 7). Find the sciatic nerve as a hyperechoic structure. The piriformis muscle can then be seen moving with its attachment site on the greater trochanter with internal and external rotation of the hip and a flexed knee (Figure 8). The probe is then directed parallel to the piriformis and the needle is inserted in the long axis view through the gluteus maximus from medial to lateral into the piriformis (Figure 9).

In order to avoid injury to the sciatic nerve, advance the needle slowly and have the patient report any neurologic symptoms (numbness, tingling, electrical impulse, etc). If these signs do occur, slowly pull the needle back and redirect it more laterally. If the injection is placed too close to the nerve, the patient may experience post-injection weakness in that leg. They should be counseled that this is transient and the strength will return.

CPT Coding: Piriformis injection with ultrasound guidance- 76942

### **Hamstring Injections**

Hamstring strains of the mid and distal hamstring myotendinous complex are common athletic injuries. These injuries can include; partial tears, full tears, inflammatory reaction, and tendon degeneration. The initial presenting symptoms will most often include the acute or subacute onset of deep buttock and thigh pain with activity. Patients with grade I injuries will usually recover quickly and do not seek medical attention. However, grade II and III strains report acutely with pain, loss of strength, transient sciatica, and posterior thigh tenderness.

Physical examination in the prone position will reveal an area slightly swollen, tender, and possibly ecchymotic. Pain is exacerbated with 90 degrees of hip flexion or resisted knee flexion. It has been reported that the more proximal the injury, the longer the recovery process<sup>16</sup>. If there is a significant hamstring rupture, a palpable knot or defect can be felt along the posterior thigh.

In the absence of a large defect, initial treatment should consist of conservative measures and physical therapy. Rest, ice, compression, and elevation (RICE) are the mainstay of initial hamstring strain treatment. This helps to decrease hemorrhage and the inflammatory process. After a couple days of rest, physical therapy can be initiated for range of motion and gradual strengthening. If these conservative measures fail to provide symptomatic improvement, and MRI can then be ordered to further evaluate the hamstring tendon. A large tear can be addressed operatively in the symptomatic patient.

However, in the setting of a symptomatic partial tear or sprain that has failed conservative management and operative intervention is not indicated, an injection can be considered. Levine et al<sup>17</sup> reported good results of corticosteroid injections in NFL football players.

### ***Hamstring Injection Technique***

The technique is rather simple. The hamstring myotendinous complex is palpated along its length on the posterior thigh with the patient in the prone position. The point of maximal tenderness is identified and a mixture of anesthetic and corticosteroid is injected intramuscularly (Figure 10). The senior authors do not employ it, but ultrasound can also be used to isolate the hamstring tendon at the insertion to the ischial tuberosity.

Complications are related to intramuscular injection and include hemorrhage and pain. However, these are very infrequent. Patients are usually restricted from activity for 48 hours and then are allowed a gradual return with physical therapy focusing on initial range of motion.

### **Hip Osteoarthritis/Labral Pathology**

Rheumatologic and recent orthopaedic literature differ when discussing primary hip osteoarthritis. While many rheumatologists and primary care physicians feel hip osteoarthritis is a primary disorder many hip surgeons feel that the incidence of idiopathic osteoarthritis of the hip is rare and that it can be typically attributed to some underlying

process or deformity<sup>18-21</sup>. Hip dysplasia of varying severity, hip impingement (CAM or Pincer), acetabular retroversion, coxa profunda, prior Legg-Calve-Perthes disease, prior slipped capital femoral epiphysis (SCFE), infection, neuropathy, avascular necrosis, or trauma can each lead to osteoarthritis. Obesity also seems to play a role in the development of hip osteoarthritis, and while it may or may not be a direct cause it likely accelerates the process or worsens the effects of the underlying deformity. Regardless of the cause, hip pain is a common presentation to both the primary care physician and orthopaedic specialist. A recent systematic review using radiographs to diagnose hip osteoarthritis found a prevalence ranging from 0.9% to 27% in the general adult population<sup>22</sup>.

Labral pathology has been increasingly recognized in a younger patient population. Scientific studies are ongoing to describe the exact role of the hip labrum, but we do know that it provides a “suction seal” for the hip joint and may assist in the contact mechanics during hip loading. In differentiation to osteoarthritis, these patients are younger with different symptoms.

In arthritic hips, patients often complain of a grinding sensation in the groin, decreased range of motion and increasing difficulty of activities of daily living including putting on their shoes or socks. Often patients will complain of a deep pain that worsens with weight bearing. Certain findings in the history should alert the physician to search for another cause of the patient’s pain. Hip osteoarthritis does not typically cause radicular or shooting pain. Pain over the greater trochanter or deep posterior pain are not typically caused by hip osteoarthritis directly, but trochanteric bursitis or posterior tendinosis can be found concomitantly with osteoarthritis of the hip. In younger patients with a suspected labral tear some will complain of a traumatic event that initiated their hip pain, but the majority will describe an insidious onset of anterior/groin pain with activities that require hip flexion.

Physical exam findings that typically accompany both hip osteoarthritis and labral tears are limitation of motion and pain localized to the groin. Typically, patients will have reduced hip flexion and hip flexion with internal rotation. Depending on the severity of the arthritis, more limitations in motion can occur. Any examination of the hip should begin with a general observation of the patient’s posture and gait pattern. A trendelenburg gait can clue the physician in to hip abductor weakness, while an antalgic gait may be seen with pain causing limited motion. A careful examination of the lumbar spine should be included as part of the hip examination.

A standard standing anterior-to-posterior (AP) pelvis radiograph, AP of the affected hip, and cross table or frog-leg lateral radiographs should be obtained in patients complaining of hip pain, especially when localized to the groin. MRI or other advanced imaging should not be needed for the diagnosis of hip arthritis, and should be reserved for patients less than the age of 60 with no radiographic evidence of osteoarthritis and physical exam findings suggestive of intraarticular hip pathology. MRI Arthrogram is



more reliable at detecting intraarticular hip pathology than MRI alone and local anesthetic with or without corticosteroid can be injected at the same time as a diagnostic and potentially therapeutic injection.

Treatment of hip osteoarthritis includes similar treatment to other forms of osteoarthritis, which include: weight reduction, anti-inflammatory medications if not contraindicated, and activity modification. Intra-articular injections can be used for diagnostic and therapeutic purposes. The ultimate treatment is a total hip arthroplasty, which offers patients a very high success rate and dramatic improvements in pain and functional scores. However, as with any surgery complications exist such as infection, fracture, prosthesis failure, prosthesis wear, squeaking (with some implant materials), and dissatisfaction.

The treatment of labral tears also includes initial conservative measures with avoidance of offending activities, physical therapy and non-steroidal antiinflammatories. If these measure fail, hip arthroscopy can provide effective relief of symptoms and return to activity.

#### ***Indication for injection***

Intra-articular hip injection can be performed for therapeutic or diagnostic purposes. The physician can confirm a diagnosis of an intra-articular process using a diagnostic injection of local anesthetic, which can be combined with corticosteroid for a therapeutic effect. Corticosteroid may be avoided in the young patient in which the injection may be used to help diagnose a labral tear; however, when there is subtle to severe osteoarthritis, corticosteroid can be used if there are no contraindications. Intra-articular steroid injections can help the clinician differentiate between intra-articular hip pain, or pain radiating from the lower back<sup>23</sup>. Interestingly, a recent study of 40 patients with monolateral severe hip OA undergoing a series of 3 PRP injected over a 3 week period demonstrated significant reductions in VAS, WOMAC, and Harris hip subscores for pain and function both at 7 weeks and 6 months. Fifty-eight percent of patients achieved at least a 30% reduction in their pain scores, which was deemed the clinically significant difference<sup>24</sup>.

#### ***Injection technique***

Typically, the most reliable and comfortable method of performing a hip injection is performed in the supine position, with the needle directed from anterolateral (Figure 11). With the patient lying supine on a radiolucent table, the anterior superior iliac spine (ASIS) is palpated and marked. A line is then drawn down the long axis of the femur from this spot. Needle placement should stay lateral to this line to avoid risk to the femoral nerve and vessels. The femoral vessels can typically be palpated and can be marked for further assurance. Radiographic guidance can then be used beginning at a point approximately 2.5cm distal to the ASIS and fluoroscopy can verify using a radiopaque instrument that this location is in line with the femoral head. The entrance

site it then marked and local anesthetic, typically 1% lidocaine, is used to anesthetize the skin and subcutaneous tissues following sterile prep.

Using sterile technique a 22 gauge spinal needle with a 10cc syringe filled with air attached is then introduced into the skin and directed towards the center of the femoral head on the AP radiograph. Once the needle reaches the center of the femoral head on xray the air in the syringe is injected and a fluoroscopic radiograph is taken of the air arthrogram to confirm intraarticular placement of the needle (Figure 12). We then attach a separate syringe of 2cc of 1% lidocaine, 2cc of 0.5% Marcaine and 1 cc of 40mg depomedrol. This is injected into the joint by keeping the needle directly on the femoral neck and pulling back only enough to allow the medication to flow freely.

### ***Injection after care***

Ice to the injection site is typically recommended. Refraining from strenuous activity the day of the injection is also typically advised. Otherwise there are no limitations following injection.

### ***Complications***

Potential complications include a rise or irregularity in blood sugars in poorly controlled diabetic patients, intravascular injection of local anesthetics, and improper placement of the medication (inability to inject into the joint).

### ***CPT and ICD-9 code***

76942 Ultrasonic guidance for needle placement

20610 Arthrocentesis, aspiration and/or injection; major joint or bursa

77002 fluoroscopic guidance for needle placement (modifier 26 if do not own the xray machine-professional component only)

715.5 osteoarthritis - hip

### **Oseitis Pubis**

Sports related groin injuries occur with an incidence of 0.5% to 6.2%<sup>25</sup>, with even higher rates in soccer players. The differential diagnosis for groin pain in an athlete includes: osteitis pubis, sports hernia, referred low back pain or genitourinary pain, intra-articular hip pathology, stress fractures, and musculotendinous strains. Osteitis pubis is defined as a painful, inflammatory process of the pubic symphysis and surrounding structures.

Urologic and gynecologic procedures, rheumatological conditions, trauma, pregnancy and athletics are predisposing factors thought to contribute to the development of osteitis pubis. Pain is caused and worsened by sprinting, kicking, twisting and cutting, and thus participants in sports such as soccer, football, ice hockey, rugby, and running are at higher likelihood of developing this condition<sup>26</sup>.

On physical examination, there is tenderness to palpation of the pubic symphysis. Resisted strength testing of the adductor muscles as well as the lower abdominal muscles often elicits pain due to their pull on the pelvis. Adductor stretching by hip abduction can also cause pain. There is significant overlap between this and other disorders causing

chronic groin pain in the athlete.

Radiographs are typically the first diagnostic modality ordered as irregularity at the symphysis can sometimes be seen on this inexpensive test, especially in chronic cases. MRI would likely be the next most informative test as this can demonstrate edema in the bone. A bone scan or a tagged white blood cell scan can be used to differentiate from osteomyelitis if the clinical picture is indistinct.

Treatment typically starts with anti-inflammatory medications (NSAIDs) and physical therapy. Some authors describe use of compression shorts as additional therapy. Results of a systematic review of the treatment of osteitis pubis demonstrated that physical therapy and NSAID use was much more beneficial and return to play was faster the earlier the diagnosis was made and treatment was initiated<sup>27</sup>. Therapy should be directed at core stability, gluteal and adductor strength and endurance.

### **Indication for injection**

The indication for injection in this population would be in athletes who have failed conservative treatment. Studies examining corticosteroid use for osteitis pubis demonstrate a 58.6% success rate and over 20% that had no response<sup>27</sup>. This may be related to the fact that injections were reserved for athletes who did not respond to other treatments. One study noted that 3 patients that underwent acute injection all were able to return to sport within 2 weeks from the injection, indicating there may be a role for immediate injection in the acute time period<sup>26</sup>. Prolotherapy has been performed in one study with over 90% of athletes returning to sport at a mean of 9 weeks from the first injection. None of these studies were randomized controlled trials and thus the indications for injection following the diagnosis of osteitis pubis need further examination.

### ***Injection technique***

The patient is brought to a room with fluoroscopic capabilities. The patient lies supine on a radiolucent table. The physician typically can palpate the pubis, and often the symphysis. If the symphysis is not palpable an anteroposterior (AP) fluoroscopic image can be taken to localize the needle. After prepping the patient, sterile technique is used to inject local anesthetic (typically 1% lidocaine) using a 25 gauge by 1.5 inch needle in the skin initially and then through the subcutaneous tissues down to the level of the symphysis (A

**B**

Figure 13). Then a 22 gauge needle can be inserted into the symphyseal cleft. This is performed by feeling the needle meet some resistance, which will indicate the outer margins of the joint and then advancing an additional 1 cm. The feel of puncturing the fibrocartilagenous disk is described as similar to that of puncturing an intervertebral disk.<sup>28</sup> Once in the disk, 1 ml of nonionic contrast material can be injected to assure appropriate placement of the needle, outline the disk and determine if there is disk degeneration, and potentially provoke symptoms similar to a spinal diskogram.<sup>28</sup> Once the contrast material is injected a fluoroscopic AP radiograph should be obtained to

evaluate the disk morphology. Following the radiograph, a 3cc solution of 1cc 0.5% Marcaine, 1cc of 1% lidocaine, and 1cc of 40mg depomedrol is injected. Other local anesthetics and steroid medications can be substituted. The patient should then be reexamined and prior positive findings should be eliminated or reduced in severity.

### ***Injection after care***

Ice to the injection site is typically recommended following the injection. The patient should refrain from strenuous activity the day of the injection, however can return to normal activities of daily living.

### ***Complications***

No reported complications were noted in any of the studies evaluating cortisone and prolotherapy for osteiti pubis. Theoretical risks include bladder puncture, infection (especially with repeated injections), and intravascular injection of local anesthetic as this is a highly vascular area. Localization should be performed with either direct palpation, ultrasound guidance or fluoroscopy. The latter two would allow the physician to evaluate the depth of the needle to assure bladder penetration does not occur.

### ***CPT and ICD-9 code***

76942 Ultrasonic guidance for needle placement

20610 Arthrocentesis, aspiration and/or injection; major joint or bursa

77002 fluoroscopic guidance for needle placement (modifier 26 if do not own the xray machine-professional component only)

733.5 osteitis pubis

843.8 sprain/strain hip or pelvis

### ***Sacroiliac Joint***

The sacroiliac (SI) joint is a diarthrodial joint that receives innervation from lumbosacral nerve roots. Fluoroscopically guided, contrast enhanced injections have shown that the SI joint is a source of primary low back pain and/or lower extremity pain in approximately 15% of patients with low back pain<sup>29,30</sup>. The most common cause of SI joint pain is idiopathic and occurs acutely or as a result of cumulative trauma. Causes of the pain have been suspected to include ligamentous or capsular tension, extraneous compression or shear forces, hypomobility or hypermobility, aberrant joint mechanics, and myofascial or kinetic chain imbalances leading to inflammation and pain<sup>31</sup>. Additionally, SI joint pain can be caused by infection, osteoarthritis, malignancy, insufficiency fracture, fracture of the SI joint after major trauma, ligamentous sprain, and stress fracture. Inflammation in the SI joint can be caused by metabolic, traumatic, or arthritic processes. Nearly 100% of patients with ankylosing spondylitis will develop sacroiliitis<sup>32</sup>. Metabolic processes, including calcium pyrophosphate crystal deposition, gout, ochronosis, hyperparathyroidism, renal osteodystrophy, and acromegaly, can progress to early degeneration, inflammation, and pain<sup>31</sup>. In pregnancy the release of relaxin and estrogen can cause loosening of the soft tissue support structure around the SI joint and lead to pain, particularly in the third trimester. Patients who have had previous

lumbar spine fusion or hip arthrodesis may transfer added stress to the SI joints. There is no universally accepted gold standard for the diagnosis of low back pain stemming from the SI joint<sup>33</sup>.

SI joint pain is referred to an area just inferior to the ipsilateral posterior superior iliac spine, which is common to other sources of spinal pain. Only 4% of patients with SI pain mark pain drawings above the level of L5<sup>32</sup>. The referral of pain to the lower extremity does not rule in or rule out SI joint pain. Slipman et al confirmed SI joint symptoms in 54 patients with the use of intra-articular blocks; 94% of patients had buttock pain, 48% thigh pain, 28% lower leg pain, 13% foot or ankle pain, 14% groin pain, and 2% had pain in the abdomen<sup>34</sup>.

No specific physical exam maneuvers that identify SI joint pain have been validated. The physical exam should include a neurologic exam, including straight leg raise and thoracolumbar spine range of motion evaluation. It should be noted that a false positive straight leg raise may occur when the affected leg is elevated to approximately 60 degrees because false dural tension symptoms are caused by sacroiliac joint motion at this degree of elevation. A hip exam should also be performed. Typically patients with SI joint pain will be neurologically intact, and may show non-dermatomal extremity sensory loss. Provocative tests (Patrick's and Gaenslen's tests), motion demand tests, true and functional leg length determinations, ligament tension tests, sacral sulcus tenderness, Gillet's test, and hip rotation tests lack scientific validity<sup>31</sup>.

Treatment goals aim to decrease pain and increase function. This is accomplished by improving joint kinematics, correcting lumbopelvic hip mechanics, establishing lumbopelvic and lower extremity muscular length and strength balance, and addressing soft tissue irritability. Additionally establishing a preventive program is important for long-term success. Physical therapy treatments follow the general principles of rehabilitation. Education and training regarding proper body mechanics and posture, aerobic conditioning, correction of flexibility and strength deficits and early mobilization are all important in the treatment of SI joint pain.

Radiofrequency neurotomy of the L5 dorsal ramus, its branches to the SI joint, and the lateral branches of the S1-S3 dorsal rami may be performed for chronic joint pain, but only after less invasive treatment options have been attempted. As an absolute last line of treatment, arthrodesis of the SI joint can be performed.

Diagnostic anesthetic blocks offer an excellent way to confirm the diagnosis of SI joint pain as well as provide a therapeutic intervention to help improve function.

### ***Injection Technique***

SI joint injections performed without the use of imaging assistance show poor target specificity and should be avoided<sup>35</sup>. Rupert et al performed a systematic review of the literature and concluded that the use of SI joint injections for diagnostic utilization is moderately supported, while the effect of therapeutic SI joint injections is not sufficiently proven<sup>36</sup>. Most studies show that intra-articular sacroiliac joint corticosteroid injections

provide therapeutic benefit for sacroiliitis in patients with spondyloarthropathy<sup>37-41</sup>, however, there are no controlled trials that show benefit for other causes of SI joint pain. Typically, patients tolerate the procedure with local anesthetic and pre-medication with anxiolytics or analgesics is not needed. The patient is placed prone on the fluoroscopy table and the sacroiliac joint is viewed fluoroscopically. It will be necessary to either position the patient in an oblique position, or use fluoroscopic equipment that permits rotation so that the appropriate view of the SI joint can be obtained. The SI joints are angled 10-30° posteriorly relative to the coronal plane and 10-20° medially relative to the sagittal plane. When prone, the posterior joint is medial and the anterior joint is lateral. A cephalad angling of the fluoroscopy tube by 20-25° can help differentiate the posteroinferior SI joint by moving it in a caudal direction. The target for needle entry is in the inferior aspect of the joint, as the superior portion is fibrous. The skin entry site is found using a metal object with the aid of fluoroscopy and is marked with a marking pen.

The skin is prepared in standard sterile fashion. The skin is appropriately anesthetized and a 22-gauge spinal needle is inserted through the anesthetized skin, aiming towards the target area. There will be a decrease in resistance once the posterior longitudinal ligament is punctured. Fluoroscopy confirms appropriate needle placement, which can be further confirmed with radio-opaque contrast dye (Figure 14). The pharmaceutical agents are then injected. A typical injection may consist of 40mg of methylprednisolone acetate with 2-3mL of 0.5% bupivacaine hydrochloride, although numerous steroid and anesthetic combinations are possible. The sciatic nerve is just anterior to the piriformis muscle. Large amounts of local anesthetic or improper needle placement may cause transient lower extremity weakness.

**ICD-9 Codes:**

724.6 Disorders of the sacrum

847.3 Sprain/strain of the sacrum

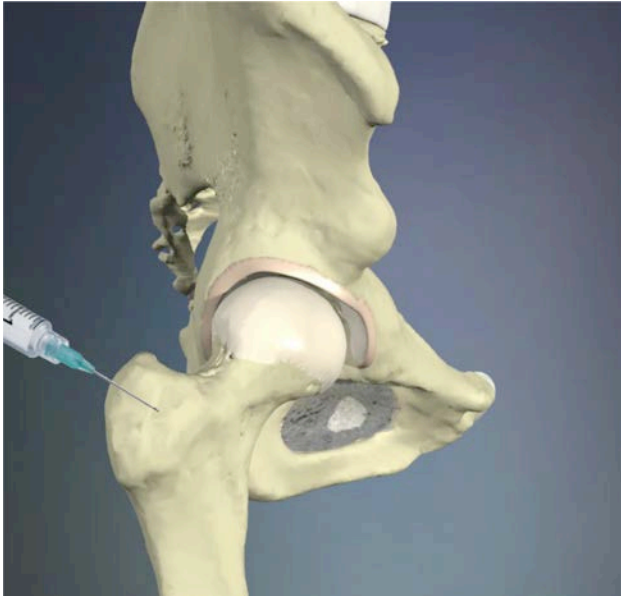
**CPT Codes:**

27096: Injection procedure for sacroiliac joint, arthrography and/or anesthetic/steroid.

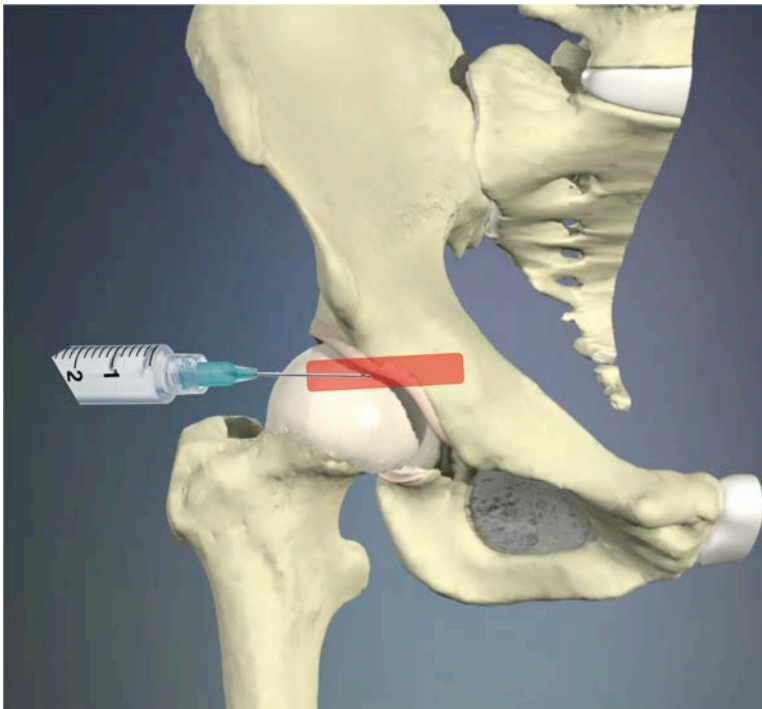
Code to be used only with image confirmation of intra-articular needle position.

77003: Fluoroscopic guidance and localization of needle or catheter tip for spine or paraspinal diagnostic or therapeutic injection procedures. Use if formal arthrography is not performed and recorded and a formal radiographic report is not issued.

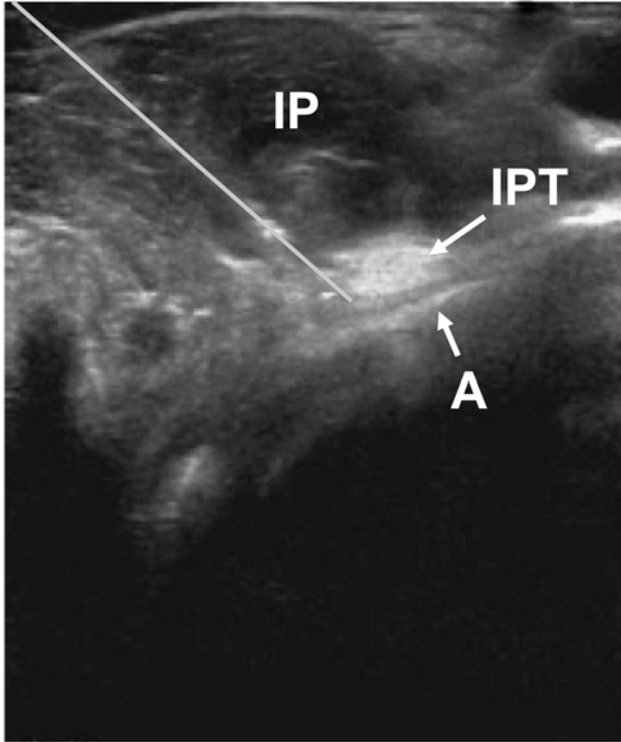
**Figures**



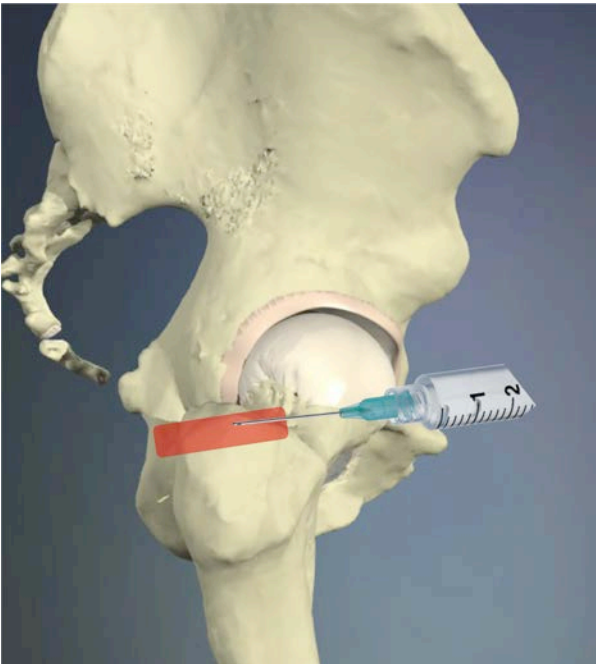
**Figure 1 – Greater trochanter injection. This is to be done at the point of maximal tenderness.**



**Figure 2 – Iliopsoas Injection. Ultrasound probe is placed transverse over the iliopsoas and the needle is inserted in the long axis.**

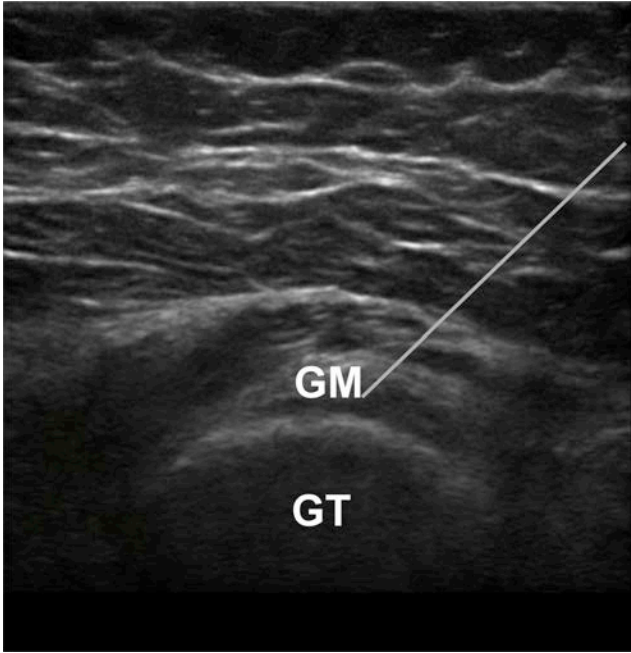


**Figure 3 – Ultrasound view of the iliopsoas. IP = Iliopsoas Muscle, IPT = Iliopsoas tendon, A = Acetabulum, Gray Line = needle trajectory from lateral to medial in the long axis.**

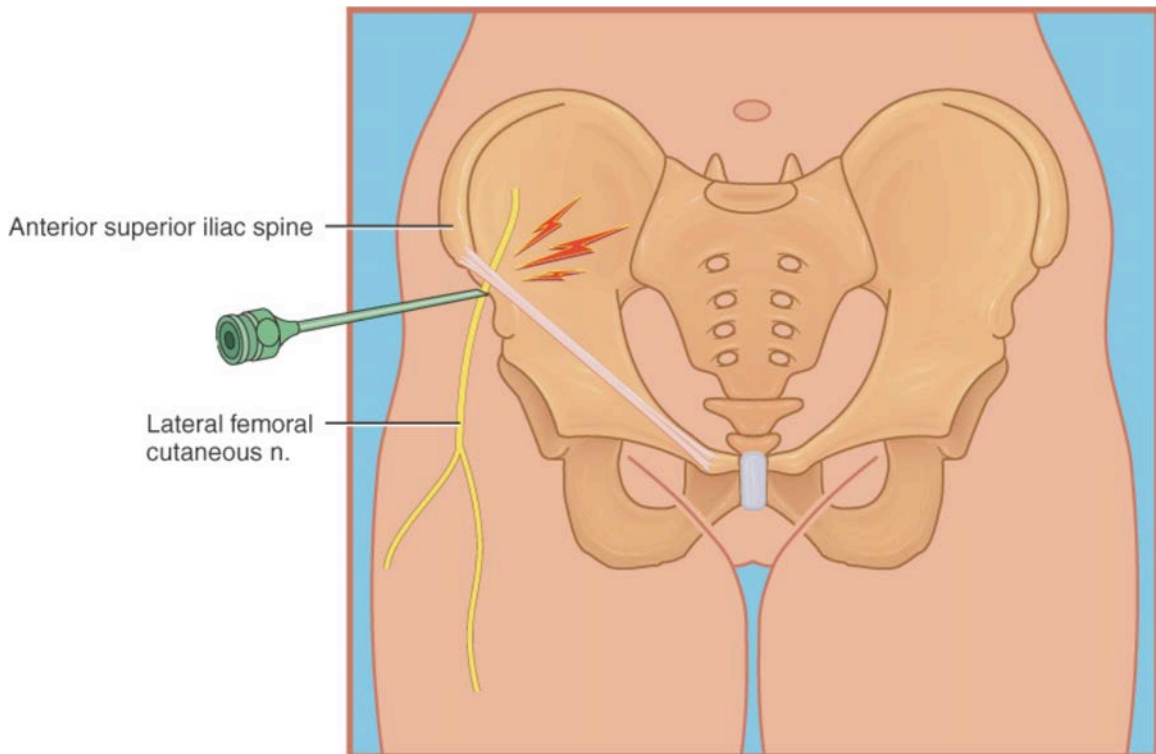


**Figure 4 – Gluteus Medius Injection. Ultrasound probe is placed in a coronally oblique orientation and the needle is inserted in the long axis from anterior.**

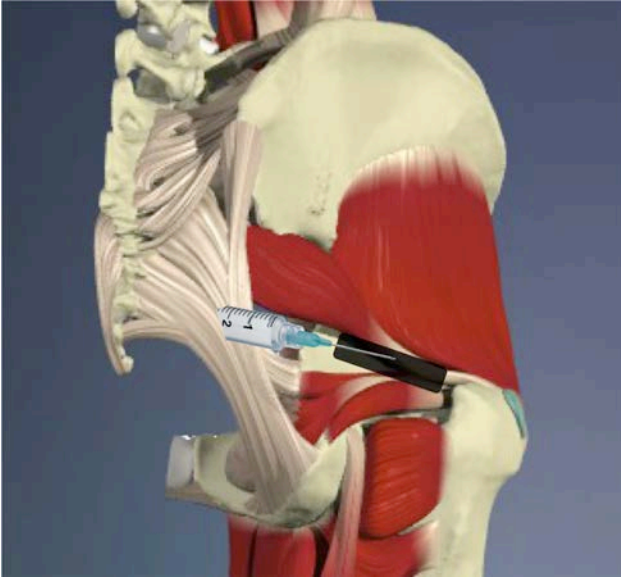




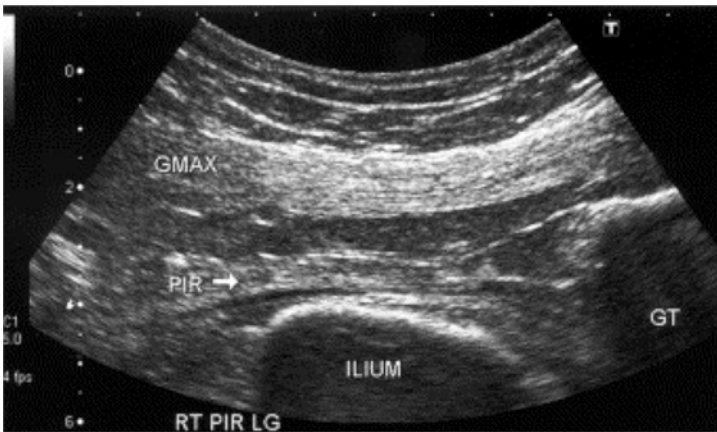
**Figure 5 – Ultrasound view of the gluteus medius injection. GM = Gluteus Medius, GT = Greater Trochanter**



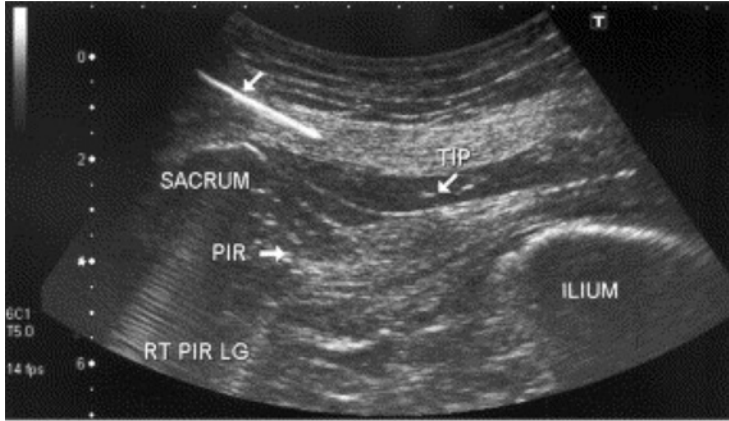
**Figure 6 – Lateral Femoral Cutaneous Nerve Injection. (Waldman S. *Atlas of Pain Management Injection Techniques*. 2<sup>nd</sup>, Elsevier 2007. Figure 97-1)**



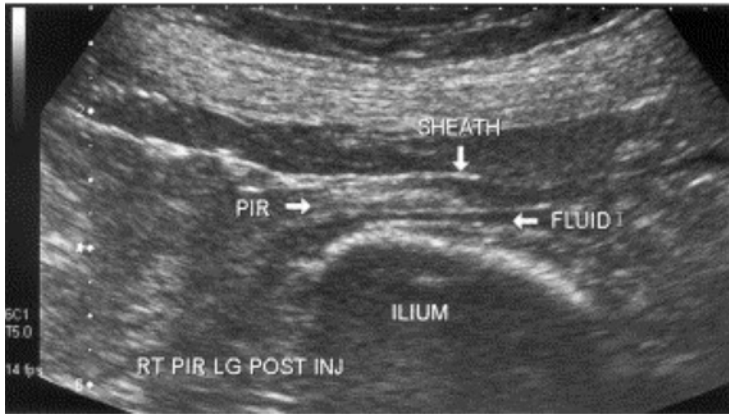
**Figure 7 – Piriformis Injection. Ultrasound is in-line with the piriformis and the needle is placed in the long axis from medial to lateral.**



**Figure 8 – Ultrasound view of the piriformis. GMAX = Gluteus Maximus, PIR = Piriformis, GT = Greater Trochanter. (Smith J, Hurdle MF, Locketz AJ, Wisniewski SJ. Ultrasound-guided piriformis injection: technique description and verification. Arch Phys Med Rehabil. 2006 Dec;87(12):1664-7. Elsevier)**

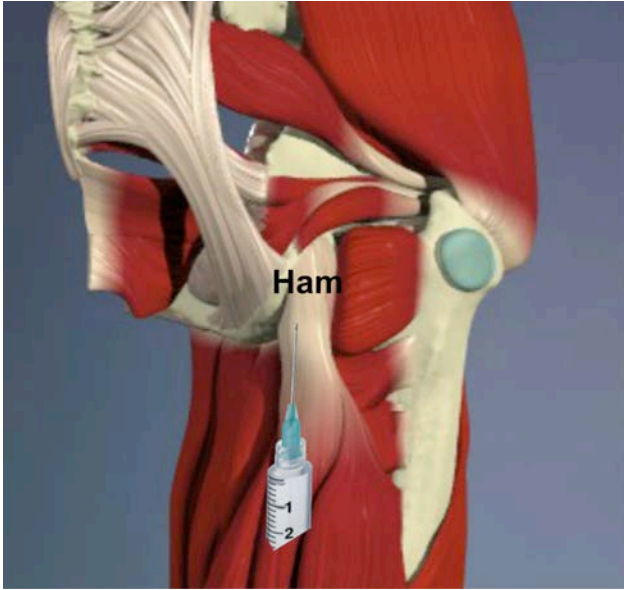


A

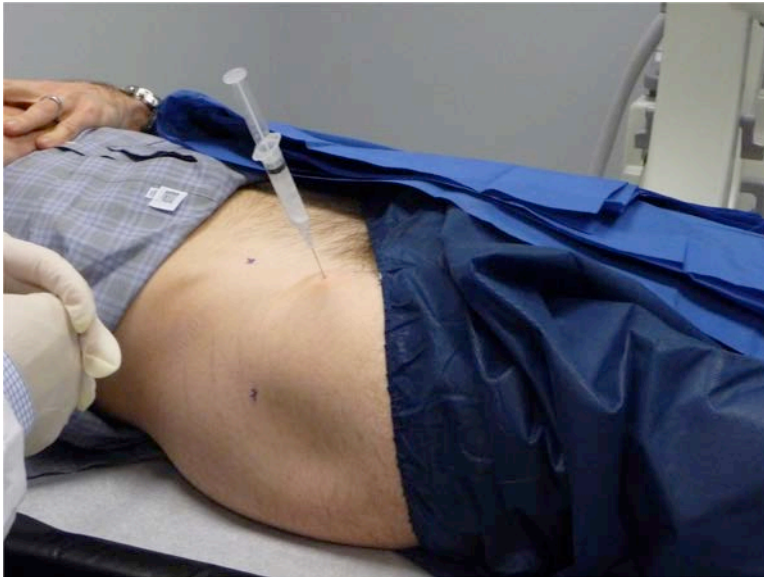

B

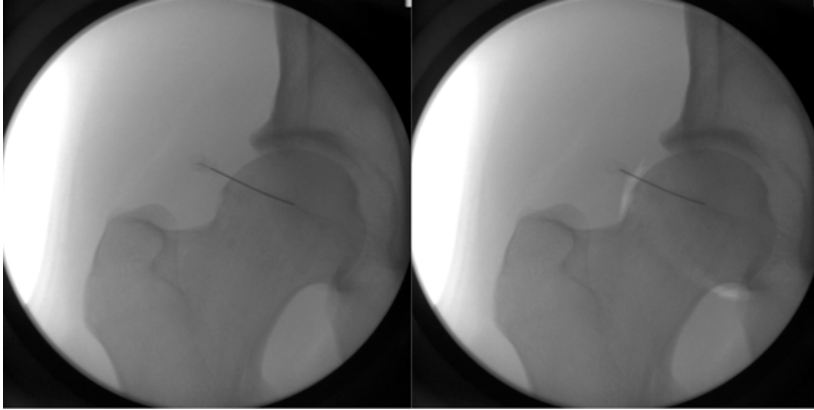
**Figure 9 – Injection of the Piriformis. Needle in the long axis from medial to lateral. A: Arrows illustrate the needle. B: Fluid is shown by the black line/area. PIR = Piriformis. (Smith J, Hurdle MF, Locketz AJ, Wisniewski SJ. Ultrasound-guided piriformis injection: technique description and verification. Arch Phys Med Rehabil. 2006 Dec;87(12):1664-7. Elsevier)**



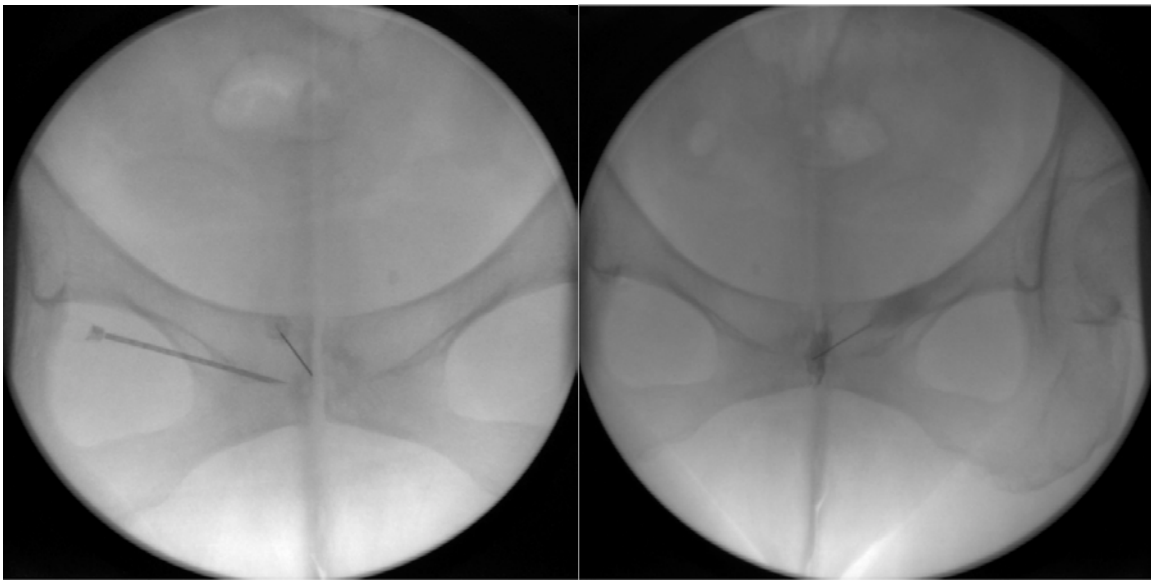
**Figure 10 – Hamstring Injection.**



**Figure 11 – Hip Injection. Location of needle.**



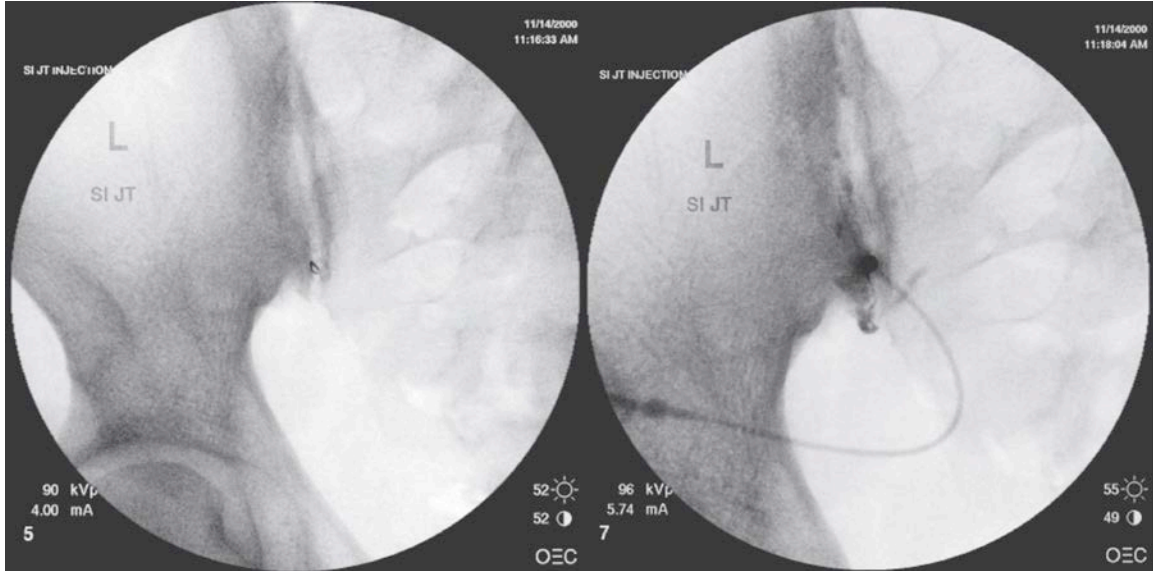
**Figure 12 – Hip Injection Fluoroscopy. Left image shows the needle entering the joint. Right image shows an air arthrogram to confirm the intra-articular location.**



**A**

**B**

**Figure 13 – Osteitis Pubis Injection. Figure A shows the insertion of the needle and figure B shows the injection of contrast and the confirmation of location with fluoroscopy.**



**Figure 14 – Sacroiliac Injection.** Left image shows the needle location under fluoroscopy. Right image shows injection of contrast medium to confirm intra-articular placement. (*Waldman S. Atlas of Pain Management Injection Techniques. 2<sup>nd</sup>, Elsevier 2007*)



## References

1. Lievens A, Bierma-Zeinstra S, Schouten B, Bohnen A, Verhaar J, Koes B. Prognosis of trochanteric pain in primary care. *Br J Gen Pract.* Mar 2005;55(512):199-204.
2. Ege Rasmussen KJ, Fano N. Trochanteric bursitis. Treatment by corticosteroid injection. *Scand J Rheumatol.* 1985;14(4):417-420.
3. Shbeeb MI, O'Duffy JD, Michet CJ, Jr., O'Fallon WM, Matteson EL. Evaluation of glucocorticosteroid injection for the treatment of trochanteric bursitis. *J Rheumatol.* Dec 1996;23(12):2104-2106.
4. Cohen SP, Narvaez JC, Lebovits AH, Stojanovic MP. Corticosteroid injections for trochanteric bursitis: is fluoroscopy necessary? A pilot study. *Br J Anaesth.* Jan 2005;94(1):100-106.
5. Johnston CA, Wiley JP, Lindsay DM, Wiseman DA. Iliopsoas bursitis and tendinitis. A review. *Sports Med.* Apr 1998;25(4):271-283.
6. Allen WC, Cope R. Coxa Saltans: The Snapping Hip Revisited. *J Am Acad Orthop Surg.* Oct 1995;3(5):303-308.
7. Trousdale RT, Cabanela ME, Berry DJ. Anterior iliopsoas impingement after total hip arthroplasty. *J Arthroplasty.* Aug 1995;10(4):546-549.
8. Kingzett-Taylor A, Tirman PF, Feller J, et al. Tendinosis and tears of gluteus medius and minimus muscles as a cause of hip pain: MR imaging findings. *AJR Am J Roentgenol.* Oct 1999;173(4):1123-1126.
9. Chung CB, Robertson JE, Cho GJ, Vaughan LM, Copp SN, Resnick D. Gluteus medius tendon tears and avulsive injuries in elderly women: imaging findings in six patients. *AJR Am J Roentgenol.* Aug 1999;173(2):351-353.
10. Bird PA, Oakley SP, Shnier R, Kirkham BW. Prospective evaluation of magnetic resonance imaging and physical examination findings in patients with greater trochanteric pain syndrome. *Arthritis Rheum.* Sep 2001;44(9):2138-2145.
11. Dwek J, Pfirrmann C, Stanley A, Pathria M, Chung CB. MR imaging of the hip abductors: normal anatomy and commonly encountered pathology at the greater trochanter. *Magn Reson Imaging Clin N Am.* Nov 2005;13(4):691-704, vii.
12. Connell DA, Bass C, Sykes CA, Young D, Edwards E. Sonographic evaluation of gluteus medius and minimus tendinopathy. *Eur Radiol.* Jun 2003;13(6):1339-1347.
13. Fishman LM, Dombi GW, Michaelsen C, et al. Piriformis syndrome: diagnosis, treatment, and outcome--a 10-year study. *Arch Phys Med Rehabil.* Mar 2002;83(3):295-301.
14. Fishman LM, Anderson C, Rosner B. BOTOX and physical therapy in the treatment of piriformis syndrome. *Am J Phys Med Rehabil.* Dec 2002;81(12):936-942.

15. Porta M. A comparative trial of botulinum toxin type A and methylprednisolone for the treatment of myofascial pain syndrome and pain from chronic muscle spasm. *Pain*. Mar 2000;85(1-2):101-105.
16. Askling CM, Tengvar M, Saartok T, Thorstensson A. Acute first-time hamstring strains during high-speed running: a longitudinal study including clinical and magnetic resonance imaging findings. *Am J Sports Med*. Feb 2007;35(2):197-206.
17. Levine WN, Bergfeld JA, TESSENDORF W, Moorman CT, 3rd. Intramuscular corticosteroid injection for hamstring injuries. A 13-year experience in the National Football League. *Am J Sports Med*. May-Jun 2000;28(3):297-300.
18. Gosvig KK, Jacobsen S, Sonne-Holm S, Palm H, Troelsen A. Prevalence of malformations of the hip joint and their relationship to sex, groin pain, and risk of osteoarthritis: a population-based survey. *J Bone Joint Surg Am*. May 2010;92(5):1162-1169.
19. Barros HJ, Camanho GL, Bernabe AC, Rodrigues MB, Leme LE. Femoral head-neck junction deformity is related to osteoarthritis of the hip. *Clin Orthop Relat Res*. Jul 2010;468(7):1920-1925.
20. Clohisy JC, Nunley RM, Carlisle JC, Schoenecker PL. Incidence and characteristics of femoral deformities in the dysplastic hip. *Clin Orthop Relat Res*. Jan 2009;467(1):128-134.
21. Clohisy JC, Beaulé PE, O'Malley A, Safran MR, Schoenecker P. AOA symposium. Hip disease in the young adult: current concepts of etiology and surgical treatment. *J Bone Joint Surg Am*. Oct 2008;90(10):2267-2281.
22. Dagenais S, Garbedian S, Wai EK. Systematic review of the prevalence of radiographic primary hip osteoarthritis. *Clin Orthop Relat Res*. Mar 2009;467(3):623-637.
23. Kaspar J, Kaspar S, Orme C, de Beer Jde V. Intra-articular steroid hip injection for osteoarthritis: a survey of orthopedic surgeons in Ontario. *Can J Surg*. Dec 2005;48(6):461-469.
24. Sanchez M, Guadilla J, Fiz N, Andia I. Ultrasound-guided platelet-rich plasma injections for the treatment of osteoarthritis of the hip. *Rheumatology (Oxford)*. Jan 2012;51(1):144-150.
25. Johnson R. Osteitis pubis. *Curr Sports Med Rep*. Apr 2003;2(2):98-102.
26. Holt MA, Keene JS, Graf BK, Helwig DC. Treatment of osteitis pubis in athletes. Results of corticosteroid injections. *Am J Sports Med*. Sep-Oct 1995;23(5):601-606.
27. Choi H, McCartney M, Best TM. Treatment of osteitis pubis and osteomyelitis of the pubic symphysis in athletes: a systematic review. *Br J Sports Med*. Jan 2011;45(1):57-64.



28. O'Connell MJ, Powell T, McCaffrey NM, O'Connell D, Eustace SJ. Symphyseal cleft injection in the diagnosis and treatment of osteitis pubis in athletes. *AJR Am J Roentgenol.* Oct 2002;179(4):955-959.
29. Schwarzer AC, Aprill CN, Bogduk N. The sacroiliac joint in chronic low back pain. *Spine (Phila Pa 1976).* Jan 1 1995;20(1):31-37.
30. Maigne JY, Aivaliklis A, Pfefer F. Results of sacroiliac joint double block and value of sacroiliac pain provocation tests in 54 patients with low back pain. *Spine (Phila Pa 1976).* Aug 15 1996;21(16):1889-1892.
31. Dreyfuss P, Michaelsen M, Pauza K, McLarty J, Bogduk N. The value of medical history and physical examination in diagnosing sacroiliac joint pain. *Spine (Phila Pa 1976).* Nov 15 1996;21(22):2594-2602.
32. Dreyfuss P, Dreyer SJ, Cole A, Mayo K. Sacroiliac joint pain. *J Am Acad Orthop Surg.* Jul-Aug 2004;12(4):255-265.
33. Hancock MJ, Maher CG, Latimer J, et al. Systematic review of tests to identify the disc, SIJ or facet joint as the source of low back pain. *Eur Spine J.* Oct 2007;16(10):1539-1550.
34. Slipman CW, Sterenfild EB, Chou LH, Herzog R, Vresilovic E. The value of radionuclide imaging in the diagnosis of sacroiliac joint syndrome. *Spine (Phila Pa 1976).* Oct 1 1996;21(19):2251-2254.
35. Rosenberg JM, Quint TJ, de Rosayro AM. Computerized tomographic localization of clinically-guided sacroiliac joint injections. *Clin J Pain.* Mar 2000;16(1):18-21.
36. Rupert MP, Lee M, Manchikanti L, Datta S, Cohen SP. Evaluation of sacroiliac joint interventions: a systematic appraisal of the literature. *Pain Physician.* Mar-Apr 2009;12(2):399-418.
37. Maugars Y, Mathis C, Berthelot JM, Charlier C, Prost A. Assessment of the efficacy of sacroiliac corticosteroid injections in spondylarthropathies: a double-blind study. *Br J Rheumatol.* Aug 1996;35(8):767-770.
38. Luukkainen R, Nissila M, Asikainen E, et al. Periarticular corticosteroid treatment of the sacroiliac joint in patients with seronegative spondylarthropathy. *Clin Exp Rheumatol.* Jan-Feb 1999;17(1):88-90.
39. Hanly JG, Mitchell M, MacMillan L, Mosher D, Sutton E. Efficacy of sacroiliac corticosteroid injections in patients with inflammatory spondyloarthropathy: results of a 6 month controlled study. *J Rheumatol.* Mar 2000;27(3):719-722.
40. Braun J, Bollow M, Seyrekbasan F, et al. Computed tomography guided corticosteroid injection of the sacroiliac joint in patients with spondyloarthropathy with sacroiliitis: clinical outcome and followup by dynamic magnetic resonance imaging. *J Rheumatol.* Apr 1996;23(4):659-664.
41. Bollow M, Braun J, Taupitz M, et al. CT-guided intraarticular corticosteroid injection into the sacroiliac joints in patients with spondyloarthropathy: indication

and follow-up with contrast-enhanced MRI. *J Comput Assist Tomogr.* Jul-Aug 1996;20(4):512-521.