

# EPIDEMIOLOGY AND ETIOLOGIES OF GLENOHUMERAL ARTHRITIS

CHRISTOPHER E. GROSS, MD  
GEOFFREY S. VAN THIEL, MD, MBA  
NIKHIL N. VERMA, MD

## INTRODUCTION

The US population is aging, but older patients remain eager to participate in exercise and physical activity. Orthopaedic surgeons are increasingly called upon to make use of improved devices, imaging modalities, and more refined surgical techniques to manage degenerative joint changes occurring in the active older patient. Although lower-extremity degenerative joint disease has received considerable attention in the literature, there has also been an increased focus on the glenohumeral joint. The pathomechanics of glenohumeral joint disease are becoming better defined and more treatment options are available, from nonsurgical care to prosthetic replacement.

## EPIDEMIOLOGY

Arthritis is responsible for more disability in the US workforce than any other factor.<sup>1,2</sup> The disease can pose serious limitations to mobility and function in an otherwise healthy adult. Approximately 21.6% of US adults (46.4 million) reported physician-diagnosed arthritis in 2005; this number is projected to skyrocket by 40% to nearly 67 million by 2030.<sup>3</sup> Women are affected by the disease more often than men. The disease also disproportionately affects obese people. Including direct and

indirect costs, in 2004, arthritis drained approximately \$281.5 billion from the US economy, an increase of 53% from 1996.<sup>4</sup>

Regardless of the cause of joint destruction, the gold standard treatment for end-stage arthritis is joint arthroplasty. After the hip and the knee, the shoulder is the joint most commonly replaced.<sup>4</sup> Of the 1.07 million total joint arthroplasties performed in 2004, 4% (43,000) were total or reverse shoulder arthroplasties. Sperling et al<sup>5</sup> reported a 20-year survival rate of 75% and 84% for hemiarthroplasty and total shoulder arthroplasty, respectively. In young patients, however, prosthetic arthroplasty may not be the best option.

The glenohumeral joint is the third-most common large joint affected by degenerative joint disease. However, glenohumeral arthritis usually is diagnosed at much later stages of disease and less frequently than arthritis of the knee or hip because the shoulder does not bear the body's weight, nor does it handle the transmitted force through the shoulder alone.<sup>6</sup> Although, as orthopaedic surgeons gain more intimate experience with the shoulder via arthroscopy, the earliest and smallest lesions are being identified. These chondral injuries are common and are seen in about 4% to 17% of patients undergoing routine shoulder arthroscopy<sup>7</sup> (Fig-

---

*Dr. Verma or an immediate family member has received royalties from Smith & Nephew; is a member of a speakers' bureau or has made paid presentations on behalf of ArthroSurface; serves as a paid consultant to Smith & Nephew; owns stock or stock options in Omeros; and has received research or institutional support from Arthrex, Smith & Nephew, Össur, and DJ Orthopaedics. Neither of the following authors nor any immediate family member has received anything of value from or owns stock in a commercial company or institution related directly or indirectly to the subject of this article: Dr. Gross and Dr. Van Thiel.*

FIGURE 1



Photograph shows the articular cartilage of the glenoid in a cadaver. Note the thick periphery.

ure 1). The true incidence of glenohumeral cartilage defects in the adult population remains undetermined, however, because these lesions are discovered during arthroscopic evaluation for shoulder pain or other pathology. Thus, the natural history of asymptomatic cartilage lesions remains largely unknown.<sup>8</sup>

Glenohumeral arthritis consists of a progressive biomechanical and biochemical degradation of the shoulder joint. Myriad factors can cause arthritis. Abnormal joint loading conditions can lead to joint incongruity, compromised synovial fluid secretion can increase friction and resistance to motion, and changes in the nutritional milieu can cause chondrocyte degeneration. These influences result in a progression of disease, increase in pain, loss of motion, and decreased function.

Cartilage defects located on the humeral head or glenoid can lead to significant glenohumeral osteoarthritis.<sup>9,10</sup> Any slight joint incongruity causes abnormal cartilage loading conditions, which can lead to further joint injury. These defects, small or large, may represent early degenerative changes of the glenohumeral joint and can mimic painful shoulder impingement.<sup>11</sup> Articular cartilage has limited regenerative capacity; therefore, full-thickness cartilage defects lack an intrinsic ability to heal.<sup>8</sup> The various factors causing arthritis are important to note because understanding the fundamental causes of the pathology can help direct research into preventive measures, new medications, and refinements of surgical techniques.

## ANATOMY

The shoulder consists of one major diarthroidal joint (the glenohumeral joint) and many articulations, including the acromioclavicular, sternoclavicular, and scapulothoracic joints. Each of these articulations can contribute to shoulder pain. The shoulder has the greatest mobility of any joint. Therefore, when arthritis affects the shoulder, many activities of daily living can be negatively impacted.<sup>12</sup>

Until recently, few studies had investigated the articular cartilage of the glenohumeral joint. Most characterizations of the cartilage of the humeral head were derived from radiographic studies. Imaging has several inherent limitations, however, given the sphericity of the humeral head and the thinness of the humeral articular cartilage, compared with that of the knee. Fox et al<sup>13</sup> found that the cartilage of the humeral head is thickest at the center (1.2 to 1.3 mm) and thins out at the periphery to less than 1.0 mm. No significant difference in cartilage thickness was noted between the superior and inferior portions of the humeral head.<sup>13</sup> The thinness of the articular cartilage makes it more prone to injury and degeneration. If the articular cartilage is injured, the subchondral bone can be more easily exposed. Soslowsky et al<sup>14</sup> studied the articular surfaces of the glenohumeral joint and found that in contrast to the humeral head, the glenoid has thicker cartilage at its periphery than at its center (Figure 2). They found that the mean thickness of the glenoid fossa was 1.31 mm, whereas the mean thickness of the peripheral articular cartilage ranged from 1.39 mm superiorly to 2.50 mm anteroinferiorly.<sup>15</sup> This difference in cartilage thicknesses between the humeral head and the glenoid, as well as contributions from the glenoid labrum, create a congruent joint.<sup>6,9,16</sup>

## CLASSIFICATION

No classification system exists specifically for articular cartilage defects of the shoulder, but existing schemes for classification of articular cartilage in the knee may be adapted. In 1961, Outerbridge<sup>17</sup> introduced a classification of chondral defects of the knee (Table 1). Some caveats regarding the Outerbridge classification system are necessary because of certain technical considerations. For example, surgeons may have difficulty discerning the difference between grade I and II because they

must rely on subjective criteria such as cartilage feel. Another pitfall is that the depth of grade III lesions can be difficult to discern.<sup>18</sup> To address these concerns, the International Cartilage Repair Society expanded the Outerbridge classification system to create a new international standard (Table 1). To grade a lesion, the surgeon must first débride the cartilage defect during arthroscopy. This helps eliminate the guesswork regarding the depth of the lesion.

To grade shoulder arthropathy following instability, Samilson and Prieto<sup>19</sup> created a radiographic classification system based on the size of the inferior glenoid or

humeral osteophyte on a standard AP radiograph (Table 2). Neither the number of recurrent dislocations nor the presence of defects of the glenoid rim and/or the humeral head was related to the severity of the arthritis.

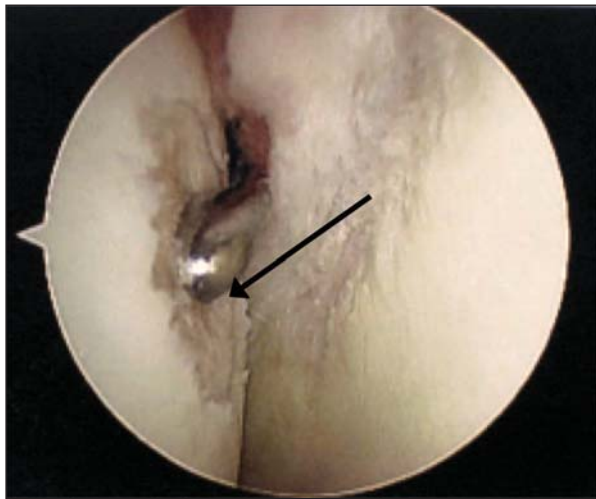
## TYPES OF GLENOHUMERAL ARTHRITIS

Glenohumeral degenerative joint disease has numerous causes and aggravators, although the exact mechanisms remain to be elucidated. Contributions to the understanding of the etiologies of glenohumeral arthritis come from joint arthroplasty registries, case series, and anecdotal accounts. The etiologies can be grouped into primary and secondary causes (Table 3), although at times, the inciting factors are difficult to find.<sup>18</sup>

### *Primary Causes of Glenohumeral Arthritis Degenerative Joint Disease*

Degenerative joint disease must not be confused with normal age-related changes in cartilage. Aging is not a pathologic process. Given that osteoarthritis is seen in aging populations, age certainly must be a factor contributing to, but not causing, the disease. Approximately 80% to 85% of women older than 70 years are affected by some degree of osteoarthritis of the shoulder.<sup>20</sup> In osteoarthritis, a lag occurs in the reparative process of normal articular cartilage in the face of wear and degradation. Many key risk factors contribute to the degenerative process and can be separated into mechanical and biochemical factors. Mechanical risk factors include compression injuries, trauma, overloading, wear, and

FIGURE 2



Arthroscopic view depicts a humeral head articular defect (arrow).

TABLE 1 Classification Systems for Osteocartilage Defects

Grade	Outerbridge	International Cartilage Repair Society
0	Normal cartilage	Normal
I	Cartilaginous softening and swelling fissures/cracks	Nearly normal: soft indentation, super
II	Partial-thickness defect with surface fissures not reaching subchondral bone or not exceeding 1.5 cm in diameter	Abnormal: lesions extending to <50% of cartilage depth
III	Fissuring extending to subchondral bone	Severely abnormal: cartilage defects >50% cartilage depth
IV	Subchondral bone exposed	Severely abnormal: defects to subchon dral bone

**TABLE 2 Samilson and Prieto Grading Characteristics of Glenohumeral Arthritis**

Grade	Inferior Osteophyte Size	Additional Findings
Mild	<3 mm	None
Moderate	3-7 mm	Slight joint irregularity
Severe	>7 mm	Joint space narrowing

**TABLE 3 Types of Glenohumeral Arthritis**

<b>Primary</b>	Degenerative joint disease Inflammatory disease (RA, PVS) Rotator cuff tear arthropathy Septic Arthritis Neuropathic arthropathy
<b>Secondary</b>	Postoperative (after capsulorrhaphy) Posttraumatic Chondrolysis Osteonecrosis

PVS = pigmented villonodular synovitis,  
RA = rheumatoid arthritis.

aging. Biochemical factors that place cartilage at risk for damage include genetic defects involving cartilage structure, hemochromatosis, Gaucher disease, alkaptonuria, Wilson disease, and acromegaly.<sup>21</sup>

Examining the effects of the biochemical properties of aging versus osteoarthritis on cartilage leads to several key differences. The water content of cartilage increases in osteoarthritis, whereas aging cartilage is more permeable and less hydrated. The collagen content in aging cartilage is relatively unchanged, whereas the collagen matrix framework in the arthritic joint becomes disorganized as the proteoglycan (protein polysaccharides that provide compressive strength) content is degraded.<sup>22</sup> In osteoarthritis, the enzymatic activities of collagenase and metalloproteinases are increased, causing a net catabolic effect on cartilage content.

In degenerative disease of the glenohumeral joint, a certain pattern of wear is often seen. Neer<sup>10</sup> reports that the glenoid usually has posterior wear because of a pos-

**FIGURE 3**

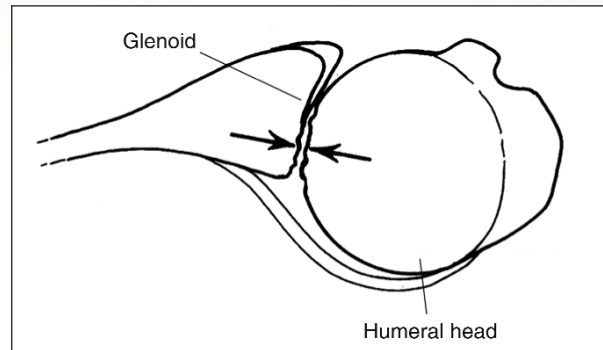
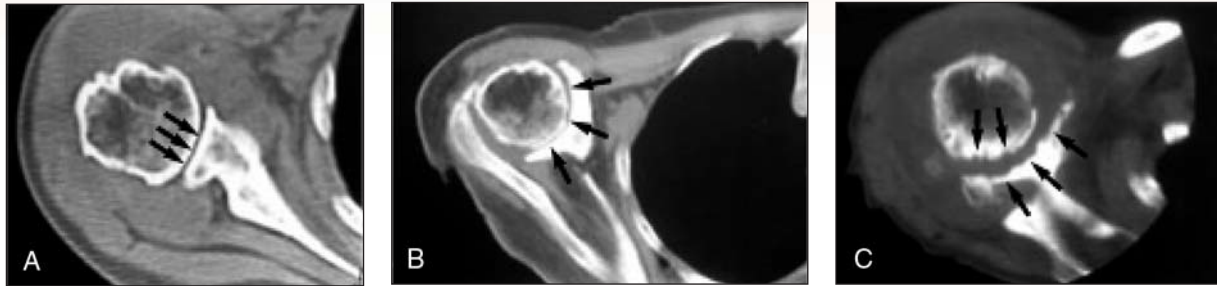

Illustration shows increased wear on the posterior aspect of the glenoid (arrows) as a result of posterior subluxation of the humeral head. (Reproduced from Millett PJ, Clavert P, Hatch GF 3rd, Warner JJ: Recurrent posterior shoulder instability. *J Am Acad Orthop Surg* 2006;14(8):464-476.)

teriorly subluxated humeral head, and the anterior glenoid articular cartilage is intact (Figure 3). This pattern of wear often leads to a biconcave glenoid with abnormal mechanics and potential posterior humeral head instability. The exact mechanism for this pathology is unknown, and the question of whether posterior wear is a consequence of a retroverted glenoid or a normal degenerative process remains to be answered.<sup>23</sup> Friedman et al<sup>23</sup> showed that in patients with primary glenohumeral arthritis, showed an increase in retroversion is seen on CT compared with healthy subjects. Walch et al<sup>24</sup> developed a more descriptive classification scheme, describing three types of glenoid morphology: Type A is symmetric erosion with a nonsubluxated humeral head. Type B is associated with the pattern described by Neer and discussed above, in which posterior erosion of the glenoid as a result of posteriorly subluxated humeral head is seen. Type C is characterized by greater than 25° of glenoid retroversion. Osteophytes, joint space narrowing, and subchondral cysts are common radiographic findings. The mechanism is as follows: subchondral cysts are cavities (thought to be caused by microfracture) filled with gelatinous material.<sup>6</sup> Degeneration of the humeral head involves central cartilage baldness surrounded by a rim of cartilage and osteophytes (Friar Tuck sign). After deterioration of the cartilage and osteochondral breakdown occur, osteophytes



FIGURE 4



Axial CT cuts of the shoulder demonstrate characteristic features of rheumatoid arthritis. **A**, Early involvement, with joint space narrowing (arrows) but maintenance of glenoid morphology. **B**, Later stage changes, with significant glenoid bone loss and erosion into the glenoid neck (arrows). **C**, Advanced changes, with extensive erosion of the glenoid and humeral head (arrows). (Reproduced from Chen AL, Joseph TN, Zuckerman JD: Rheumatoid Arthritis of the Shoulder. *J Am Acad Orthop Surg* 2003;11(1):12-24.)

and subchondral cysts form. With the loss of cartilage, joint space narrowing is often seen.

### Inflammatory Disease

Many inflammatory disorders also can cause severe glenohumeral joint damage. Rheumatoid arthritis, psoriatic arthritis, Lyme disease, hemophilia (hemarthrosis), hemochromatosis, Reiter syndrome, pigmented villonodular synovitis, and ankylosing arthritis are a few examples of conditions in which the body's immune system destroys its own joint.<sup>25</sup> Rheumatoid arthritis is by far the most common type of inflammatory arthritis. The disease affects 1% of people globally, with a female-to-male ratio of 3:1. In people older than 70 years, the disease affects about 5% of the population, with men and women affected equally.<sup>26</sup> Of patients who have had rheumatoid arthritis for more than 5 years, 91% have symptomatic glenohumeral arthritis.<sup>27</sup> Rheumatoid arthritis must be suspected in patients with morning stiffness, symmetric joint swelling and pain, and general malaise. Laboratory test results and radiologic findings help confirm the diagnosis.

Rheumatoid arthritis is likely a T-cell-mediated immune response to the synovial tissue, cartilage, and bone. The response causes microvascular injury and synovial cell proliferation. Immune mediators, such as interleukin-1 (IL-1) and tumor necrosis factor-alpha (TNF- $\alpha$ ) begin a cascade that results in erosive degradation of the joint. This cascade destroys proteoglycans and collagen in the cartilage matrix. This cascade also

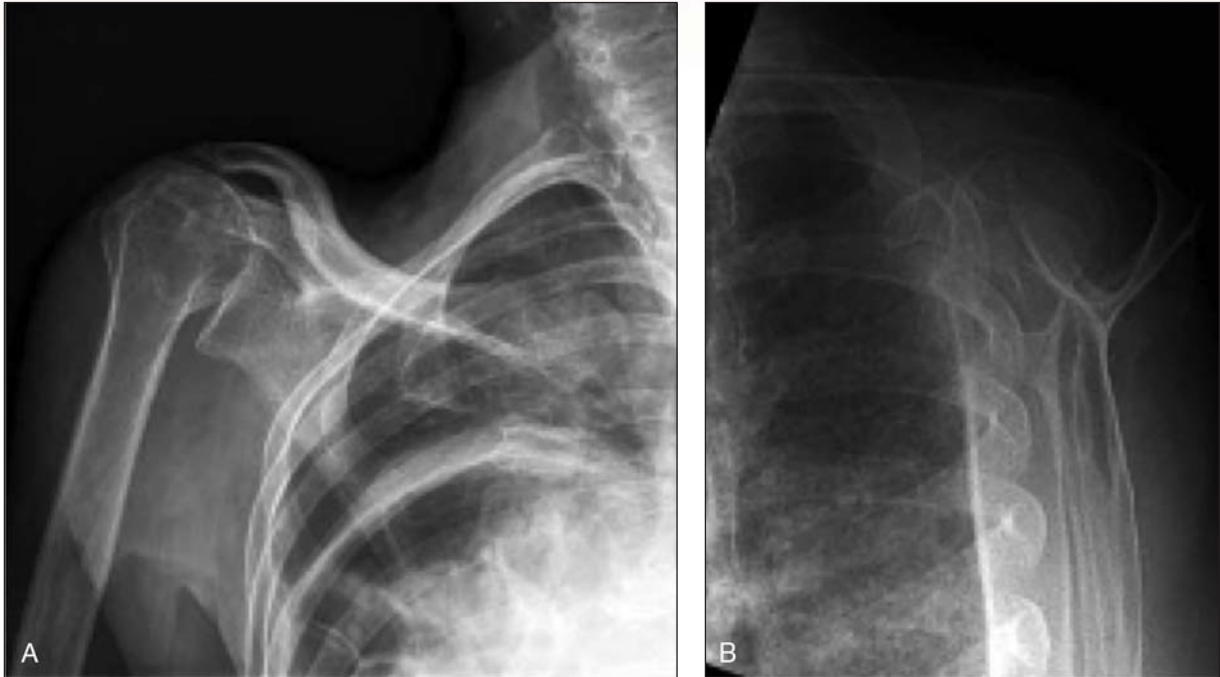leads to immune complex activation and deposition onto the joint surface, bone erosion, and the formation of a pannus (hyperplastic synovial tissue, which causes erosive changes to bone and cartilage).<sup>28</sup>

A shoulder affected by rheumatoid arthritis may present as an acute inflammatory event or as an insidious onset of swelling, pain, and later, decreased range of motion.<sup>26</sup> Not only can the glenohumeral joint be affected, but inflamed soft-tissue defects such as rotator cuff compromise are present in 75% of patients, and a full-thickness rotator cuff tears (RCTs) are present in 15% to 30% of patients.<sup>6,29</sup> Loss of motion is noticed by the patient and impairs function only with more advanced disease because the shoulder can compensate with more scapulothoracic translation and the patient can compensate by using the unaffected shoulder.

Rheumatoid arthritis in the shoulder has characteristic radiographic and arthroscopic features. One of the earliest radiographic findings is loss of bone density in the humeral head or the glenoid. Most often, symmetric and bilateral destruction of the joint space exists. Loss of cartilage is first seen superolaterally, on the articular surface of the humerus. Next, the medial glenoid becomes involved. Bone erosion and subchondral cysts also may be seen later in the progression of the disease.<sup>25</sup> In contrast to osteoarthritis, the wear pattern with rheumatoid arthritis is most often central, resulting in medialization of the joint due to progressive glenoid erosion (Figure 4).

In a patient with juvenile idiopathic arthritis, persistent arthritis of the immature skeleton produces a malde-

FIGURE 5



Radiographs of a shoulder with rotator cuff tear arthropathy. **A**, AP view demonstrates superior migration of the humeral head with degenerative changes in the glenohumeral joint, glenoid erosion, and acromial erosion as well as femoralization of the humeral head. **B**, Scapular Y view demonstrates superior migration of the humeral head and diffuse osteopenia. (Reproduced from Ecklund KJ, Lee TQ, Tibone J, Gupta R: Rotator cuff tear arthropathy. *J Am Acad Ortho Surg* 2007;15(6):340-349.)

veloped proximal humerus and glenoid cavity. Later in the course of the disease, erosion of the cartilage causes medial migration and superior subluxation of the humeral head.<sup>30</sup>

### RCT Arthropathy

RCT arthropathy, first described by Neer et al<sup>31</sup> in 1983 as “cuff-tear arthropathy,” is a clinical entity, in which massive RCTs lead to degenerative changes of the glenohumeral joint. It affects the dominant arm in women more than in men.<sup>32</sup> Gartsman and Taverna<sup>33</sup> conducted a study of 195 patients undergoing arthroscopic rotator cuff repair. Of these 195 patients, 9 (4.5%) had 1.5 cm<sup>2</sup> of eburnated bone and 17 (8.5%) had cartilage fraying or thinness. Symptoms included pain with activity and at night, joint effusion, and loss of motion. As described above, the rotator cuff plays a key role in the dynamic sta-

bilization of the shoulder throughout range of motion. During mid and end range of motion, the muscles of the rotator cuff drive the humeral head into the glenoid and labrum, allowing concentric rotation of the humeral head.<sup>34</sup> This concavity-compression is disrupted as a result of massive RCTs. This disruption of the force coupling causes instability and allows superior translation of the humerus, decreasing the acromiohumeral distance.

When the articular cartilage of the humeral head strikes the coracoacromial arch, erosion begins to occur superiorly. This causes femoralization of the humeral head and acetabularization of the glenoid cavity.<sup>35</sup> Superior subluxation of the humeral head causes subacromial impingement and subsequent degeneration of the superior lip of the glenoid, acromioclavicular joint, acromion, and coracoid, leading to further loss of subchondral bone<sup>36</sup> (Figure 5).

In an MRI study conducted by Sher et al,<sup>37</sup> 28% of patients (13 of 96) older than 60 years had a full-thickness RCT, and about 4% of these patients (1 of 96) went on to develop RCT arthropathy. Because the natural history of an RCT is not known, other factors besides mechanics must contribute to the development of the joint disease. Neer et al<sup>31</sup> proposed that nutritional factors also must play a role in the progression of the disease. A decrease in function and motion leads to osteopenia and to changes in the water and glycosaminoglycan content of the articular cartilage. Because cartilage needs compressive stimulation and force loading to remain competent, the cartilage begins to atrophy. Additionally, when the rotator cuff fails, synovial fluid may communicate with the subacromial and subdeltoid space. Capsular pressure decreases and the joint fluid quantity decreases, which leads to additional cartilage atrophy.<sup>31</sup>

Collins and Harryman<sup>38</sup> expanded on Neer's pathogenesis theory of RCT arthropathy by including calcium crystals as a causative factor, as seen in the Milwaukee shoulder. When the humeral head migrates superiorly and strikes the coracoacromial arch, particulate debris is created. This process is manifested as a joint effusion, synovial thickening, and crystal formation. The response to the crystals and debris causes further destruction of the rotator cuff and degeneration of the glenohumeral joint.

### Septic Arthritis

The shoulder is not often affected by infectious arthritis,<sup>39</sup> but when it is, the results can be devastating. Untreated septic arthritis can result in chondrolysis and osteolysis. The patient often has undergone previous surgery or hardware placement that may predispose the shoulder to bacterial seeding. The medically debilitated or transplant patient with multiple comorbidities frequently succumbs to septic arthritis.<sup>39</sup> Suspicion also must be high for septic arthritis in a pathologic shoulder (eg, with rheumatoid arthritis or a massive RCT). Symptoms include erythema and swelling of the shoulder. Additionally, severe pain is often encountered during passive range of motion. The surgeon should have a low threshold for aspirating the shoulder to firmly diagnose septic arthritis when clinical suspicion of the condition is high. The types of causative organisms seen in the native joint are different from those seen in one

that has undergone rotator cuff repair. The most common type of nonsurgical bacteria is *Staphylococcus aureus*, whereas the most common organism that seeds postoperative shoulders is *Propionibacterium acnes*.<sup>40</sup>

### Neuropathic Arthropathy

Neuropathic arthropathy of the shoulder is a rare phenomenon that occurs when the normal neurologic factors that help protect a joint (eg, nociception and joint position sense) are lost as a result of joint denervation. The loss of protection of the joint causes abnormal loading conditions that can lead to humeral head resorption and glenohumeral cartilage degeneration. The synovial fluid also might be diminished in quantity, causing increased joint friction.<sup>6</sup> The patient commonly presents with generalized upper extremity neurologic symptoms such as weakness, sensory changes, paresthesias, and diminished reflexes.<sup>41</sup> Shoulder pain and swelling are also quite common. The most common causes of neuroarthropathy are syringomyelia (cyst or syrinx that forms within the spinal canal) and late complications of diabetes. Meyer et al<sup>42</sup> reported that neuropathic arthropathy develops in 25% of patients with syringomyelia, and that 80% of these arthropathies are in the upper extremities.

### Secondary Causes of Glenohumeral Arthritis

#### Chondrolysis

Chondrolysis is the rapid destruction of cartilage matrix within the glenohumeral joint. Postarthroscopic glenohumeral chondrolysis (PAGCL) is of particular concern, given that roughly 230,000 shoulder arthroscopic procedures are performed in the United States every year.<sup>43</sup> Several differences between osteoarthritis and chondrolysis differ in several ways, but both lead to the same result: cartilage death. Chondrolysis usually occurs in younger patients as a result of a specific cartilage insult and develops within months of the injury. On the other hand, osteoarthritis is mostly idiopathic and takes years, even decades, to develop in an older patient.<sup>44</sup> Hansen et al<sup>44</sup> have described a list of diagnostic criteria for PAGCL, including increased shoulder pain, decreased range of motion, shoulder crepitus not associated with range of motion, and glenohumeral joint space narrowing seen on radiographs.

Several causative factors of chondrolysis have been described in the literature. The list includes bupivacaine and lidocaine administered by injection or pain pump, and intra-arthroscopic factors.<sup>45,46</sup> A meta-analysis of the literature on PAGCL lists many intraoperative causes, such as hypotonic irrigation fluid (normal saline, lactated ringers can lead to decreased cartilage viability); radiofrequency ablation (thermal injury); scuffing or gouging of cartilage during tool manipulation or trochar insertion; proud anchors; and suture knots at the level of the articular cartilage, causing abrasion.<sup>45</sup>

The pathomechanics of chondrolysis have not been elucidated thus far. Solomon et al<sup>45</sup> suggested that mechanical, thermal, and chemical factors initiate cartilage injury. The cartilage response is exaggerated, causing inflammation and cellular death, which leads to degradation of the cartilage matrix and further chondrocyte apoptosis in unaffected layers. Eventually, the loss of joint congruity and an increase in friction lead to accelerated wear (Figure 6).

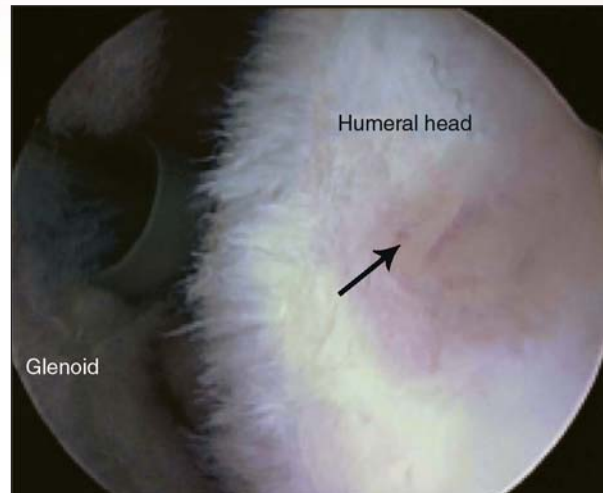
### After Capsulorrhaphy

Capsulorrhaphy is a well-described causative factor in glenohumeral arthritis.<sup>47</sup> The surgical procedures that aim to repair chronic instability may result in overtightening of the capsule. Surgical procedures that have been implicated in causing joint surface deterioration include open Bankart reconstructions and Putti-Platt, Bristow, and Magnuson-Stack procedures.<sup>48,49</sup> The Putti-Platt procedure for instability involves tightening and shortening the subscapularis and capsule. This reduces external rotation and can lead to an internal rotation contracture and posterior subluxation of the humeral head.<sup>50</sup> This chronic posterior translation of the humeral head causes posterior glenoid wear. Conversely, if a procedure results in overtightening of the posterior capsule, then chronic anterior humeral subluxation can cause anterior glenoid wear. Van der Zwaag et al<sup>51</sup> analyzed data from 66 shoulders repaired with the Putti-Platt procedure, with a mean follow-up of 22 years. The authors found that 40 (61%) had osteoarthritic changes and 17 (26%) had moderate to severe arthrosis.

### Trauma

Traumatic events, whether acute or chronic, have been linked to the eventual development of glenohumeral

FIGURE 6



Arthroscopic view of the shoulder of a young patient with rapidly progressive chondrolysis. The humeral cartilage is globally affected, with marked lack of cartilage (arrow).

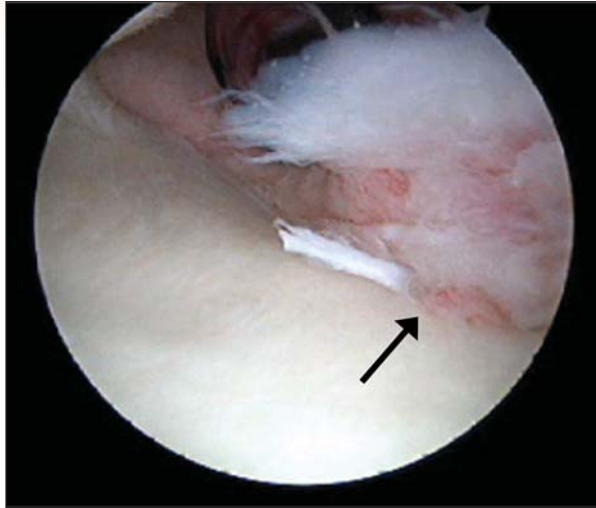
arthritis.<sup>9</sup> Acute events are singular episodes that cause shearing or compressive forces across the glenohumeral joint, causing articular cartilage damage. According to Marx et al,<sup>52</sup> a patient who has had a single shoulder dislocation has a 19-times higher likelihood of developing secondary degenerative joint disease of the glenohumeral joint than does a person who has never had an acute shoulder injury. Although the articular cartilage lesion might be difficult to see immediately on radiographs, subchondral bone damage can be seen on MRI in the form of bone bruising.

Chronic instability has been well established as a cause of early glenohumeral arthritis.<sup>53</sup> A chronic (> 6-month duration) and unreduced shoulder dislocation can cause deformation of the humeral head such that smooth motion is disrupted by the abnormal contours of the humerus and glenoid. In these cases, the articular cartilage of the humeral head may be replaced with scar tissue or fibrocartilage.<sup>10</sup>

Recent literature on acute, first-time glenohumeral subluxation events suggests that Hill-Sachs lesions (compression fractures on the posterolateral humeral head with persistent anterior instability) and Bankart lesions (avulsion injuries of the anteroinferior labrum at the inferior



FIGURE 7



Arthroscopic view shows a glenolabral articular disruption (GLAD) lesion (arrow).

glenohumeral ligament complex) are extremely common.<sup>54</sup> Buscayret et al<sup>55</sup> showed that the presence of a Hill-Sachs lesion is an independent risk factor contributing to glenohumeral arthritis. The other risk factors discovered were presence of an RCT, older age at time of dislocation, time from dislocation to surgical management, and presence of a glenoid rim impaction fracture. Glenolabral articular disruption (GLAD) injuries, a possible source of glenohumeral articular cartilage damage, often occur when the shoulder is forced into adduction from an externally rotated, abducted position<sup>18,56</sup> (Figure 7). No literature to date directly links specific GLAD lesions to glenohumeral arthritis, although a GLAD lesion is essentially a Bankart lesion with articular cartilage damage. Patients with highly stressed shoulders, such as overhead throwing athletes, experience repeated overload conditions and microtrauma to the glenohumeral joint. The mechanics of the glenohumeral joint are disrupted during repeated humeral head impact against the posterosuperior glenoid, which creates cartilage lesions near the insertion of the supraspinatus tendon.<sup>7</sup>

### Osteonecrosis

Osteonecrosis is a common cause of secondary degenerative glenohumeral disease, although it may have an

idiopathic cause. The most common causes of osteonecrosis are chronic systemic steroid use, injection of corticosteroid into the joint, radiation therapy (especially for breast cancer), excessive alcohol intake, sickle-cell crisis, immunosuppressive medications taken by transplant patients, and other vasculitides.<sup>6</sup> In the Ficat-Arlet radiologic staging system, radiographs initially reveal osteosclerosis, and then lucency, as the bone erodes.<sup>57</sup> In the final stages of osteonecrosis, the subchondral bone collapses, causing abnormal contact between the irregular humeral head and the glenoid.

### CONCLUSION

Modern orthopaedic shoulder surgery is adapting constantly to meet the needs of the more active patient. Rapid advances in technology allow orthopaedic surgeons to better elucidate the pathomechanics of shoulder arthritis and develop novel treatments for the young, active patient. These techniques comprise a spectrum from benign neglect to biologic replacement. As surgeons gain a better understanding of the anatomy, biology, and natural history of arthritic lesions, treatments will become more individualized and more effective.

### REFERENCES

1. Stoddard S, Jans L, Ripple J, Krause L: Chartbook on work and disability in the United States, 1998, in *An InfoUse Report*. Washington DC: U.S. National Institute on Disability and Rehabilitation Research, 1998.
2. Centers for Disease Control and Prevention (CDC): Prevalence of disabilities and associated health conditions among adults—United States, 1999. *MMWR Morb Mortal Wkly Rep* 2001;50(7):120-125.
3. Hootman JM, Helmick CG: Projections of US prevalence of arthritis and associated activity limitations. *Arthritis Rheum* 2006;54(1):226-229.
4. American Academy of Orthopaedic Surgeons: Arthritis and related conditions, in Jacobs JJ: *The Burden of Musculoskeletal Diseases in the United States: Prevalence, Societal and Economic Cost*. Rosemont, IL, American Academy of Orthopaedic Surgeons, 2008.
5. Sperling JW, Cofield RH, Rowland CM: Minimum fifteen-year follow-up of Neer hemiarthroplasty and total shoulder arthroplasty in patients aged fifty years or younger. *J Shoulder Elbow Surg* 2004;13(6):604-613.

6. Matsen FA III, Rockwood CA, Wirth MA, Lippitt SB, Parsons M: Glenohumeral arthritis and its management, in Rockwood C, Matsen F III, Wirth M, Lippitt S, eds: *The Shoulder*, ed 3. Philadelphia, Saunders, 2004, vol 2, pp 879-1009.
7. Paley KJ, Jobe FW, Pink MM, Kvitne RS, ElAttrache NS: Arthroscopic findings in the overhand throwing athlete: Evidence for posterior internal impingement of the rotator cuff. *Arthroscopy* 2000;16(1):35-40.
8. Cole BJ, Yanke A, Provencher MT: Nonarthroplasty alternatives for the treatment of glenohumeral arthritis. *J Shoulder Elbow Surg* 2007;16(Suppl 5):S231-S240.
9. Hsu HC, Luo ZP, Stone JJ, Huang TH, An KN: Correlation between rotator cuff tear and glenohumeral degeneration. *Acta Orthop Scand* 2003;74(1):89-94.
10. Neer CS II: Replacement arthroplasty for glenohumeral osteoarthritis. *J Bone Joint Surg Am* 1974;56(1):1-13.
11. Ellman H, Harris E, Kay SP: Early degenerative joint disease simulating impingement syndrome: Arthroscopic findings. *Arthroscopy* 1992;8(4):482-487.
12. Cooper DE, O'Brien SJ, Warren RF: Supporting layers of the glenohumeral joint: An anatomic study. *Clin Orthop Relat Res* 1993(289):144-155.
13. Fox JA, Cole BJ, Romeo AA, et al: Articular cartilage thickness of the humeral head: An anatomic study. *Orthopedics* 2008;31(3):216.
14. Soslowky LJ, Flatow EL, Bigliani LU, Mow VC: Articular geometry of the glenohumeral joint. *Clin Orthop Relat Res* 1992(285):181-190.
15. Yeh LR, Kwak S, Kim YS, et al: Evaluation of articular cartilage thickness of the humeral head and the glenoid fossa by MR arthrography: Anatomic correlation in cadavers. *Skeletal Radiol* 1998;27(9):500-504.
16. Kelkar R, Wang VM, Flatow EL, et al: Glenohumeral mechanics: A study of articular geometry, contact, and kinematics. *J Shoulder Elbow Surg* 2001;10(1):73-84.
17. Outerbridge RE: The etiology of chondromalacia patellae. *J Bone Joint Surg Br* 1961;43-B:752-757.
18. Elser F, Braun S, Dewing CB, Millett PJ: Glenohumeral joint preservation: Current options for managing articular cartilage lesions in young, active patients. *Arthroscopy* 2010;26(5):685-696.
19. Samilson RL, Prieto V: Dislocation arthropathy of the shoulder. *J Bone Joint Surg Am* 1983;65(4):456-460.
20. Brandt K, Kovalov-St John K: Osteoarthritis, in Wilson JD Braunwald E, Isselbacher KJ, et al, eds: *Harrison's Principles of Internal Medicine*, ed 12. New York, NY, McGraw-Hill, 1991.
21. Schumacher H: Secondary osteoarthritis, in Moskowitz RW, Howell DS, Goldberg VM, Mankin HJ, eds: *Osteoarthritis: Diagnosis and Surgical Management*, ed 2. Philadelphia, WB Saunders, 1993, pp 367-398.
22. Mankin HJ, Dorfman H, Lippiello L, Zarins A: Biochemical and metabolic abnormalities in articular cartilage from osteo-arthritic human hips: Part II. Correlation of morphology with biochemical and metabolic data. *J Bone Joint Surg Am* 1971;53(3):523-537.
23. Friedman RJ, Hawthorne KB, Genes BM: The use of computerized tomography in the measurement of glenoid version. *J Bone Joint Surg Am* 1992;74(7):1032-1037.
24. Walch G, Badet R, Boulahia A, Khoury A: Morphologic study of the glenoid in primary glenohumeral osteoarthritis. *J Arthroplasty* 1999;14(6):756-760.
25. Cuomo F, Greller MJ, Zuckerman JD: The rheumatoid shoulder. *Rheum Dis Clin North Am* 1998;24(1):67-82.
26. Chen AL, Joseph TN, Zuckerman JD: Rheumatoid arthritis of the shoulder. *J Am Acad Orthop Surg* 2003;11(1):12-24.
27. Petersson CJ: Painful shoulders in patients with rheumatoid arthritis: Prevalence, clinical and radiological features. *Scand J Rheumatol* 1986;15(3):275-279.
28. Shiozawa S, Shiozawa K: A review of the histopathological evidence on the pathogenesis of cartilage destruction in rheumatoid arthritis. *Scand J Rheumatol Suppl* 1988;74:65-72.
29. Curran JF, Ellman MH, Brown NL: Rheumatologic aspects of painful conditions affecting the shoulder. *Clin Orthop Relat Res* 1983(173):27-37.
30. Thomas S, Price AJ, Sankey RA, Thomas M: Shoulder hemiarthroplasty in patients with juvenile idiopathic arthritis. *J Bone Joint Surg Br* 2005;87(5):672-676.
31. Neer CS II, Craig EV, Fukuda H: Cuff-tear arthropathy. *J Bone Joint Surg Am* 1983;65(9):1232-1244.
32. Collins DN: Pathophysiology, classification, and pathoanatomy of glenohumeral arthritis and related disorders, in Iannotti JP, and Williams GR, eds. *Disorders of the Shoulder: Diagnosis and Management*. Philadelphia, PA, Lippincott Williams & Wilkins, 1999, pp 421-470.
33. Gartsman GM, Taverna E: The incidence of glenohumeral joint abnormalities associated with full-thick-

- ness, reparable rotator cuff tears. *Arthroscopy* 1997;13(4):450-455.
34. Labriola JE, Lee TQ, Debski RE, McMahon PJ: Stability and instability of the glenohumeral joint: The role of shoulder muscles. *J Shoulder Elbow Surg* 2005;14(Suppl 1):S32-S38.
  35. Ecklund KJ, Lee TQ, Tibone J, Gupta R: Rotator cuff tear arthropathy. *J Am Acad Orthop Surg* 2007;15(6):340-349.
  36. Zeman CA, Arcand MA, Cantrell JS, Skedros JG, Burkhead WZ Jr: The rotator cuff-deficient arthritic shoulder: Diagnosis and surgical management. *J Am Acad Orthop Surg* 1998;6(6):337-348.
  37. Sher JS, Uribe JW, Posada A, Murphy BJ, Zlatkin MB: Abnormal findings on magnetic resonance images of asymptomatic shoulders. *J Bone Joint Surg Am* 1995;77(1):10-15.
  38. Collins DN, Harryman DT II: Arthroplasty for arthritis and rotator cuff deficiency. *Orthop Clin North Am* 1997;28(2):225-239.
  39. Lossos IS, Yossepowitch O, Kandel L, Yardeni D, Arber N: Septic arthritis of the glenohumeral joint: A report of 11 cases and review of the literature. *Medicine (Baltimore)* 1998;77(3):177-187.
  40. Duncan SF, Sperling JW: Treatment of primary isolated shoulder sepsis in the adult patient. *Clin Orthop Relat Res* 2008;466(6):1392-1396.
  41. Hatzis N, Kaar TK, Wirth MA, Toro F, Rockwood CA Jr: Neuropathic arthropathy of the shoulder. *J Bone Joint Surg Am* 1998;80(9):1314-1319.
  42. Meyer GA, Stein J, Poppel MH: Rapid osseous changes in syringomyelia. *Radiology* 1957;69(3):415-418.
  43. Life Science Intelligence: *U.S. Markets for Arthroscopy*. Available at: <http://www.lifescienceintelligence.com/market-reports-page.php?id=A315>. Accessed November 3, 2011.
  44. Hansen BP, Beck CL, Beck EP, Townsley RW: Postarthroscopic glenohumeral chondrolysis. *Am J Sports Med* 2007;35(10):1628-1634.
  45. Solomon DJ, Navaie M, Stedje-Larsen ET, Smith JC, Provencher MT: Glenohumeral chondrolysis after arthroscopy: A systematic review of potential contributors and causal pathways. *Arthroscopy* 2009;25(11):1329-1342.
  46. Busfield BT, Romero DM: Pain pump use after shoulder arthroscopy as a cause of glenohumeral chondrolysis. *Arthroscopy* 2009;25(6):647-652.
  47. Cameron ML, Kocher MS, Briggs KK, Horan MP, Hawkins RJ: The prevalence of glenohumeral osteoarthritis in unstable shoulders. *Am J Sports Med* 2003;31(1):53-55.
  48. Brophy RH, Marx RG: Osteoarthritis following shoulder instability. *Clin Sports Med* 2005;24(1):47-56.
  49. O'Driscoll SW, Evans DC: Long-term results of staple capsulorrhaphy for anterior instability of the shoulder. *J Bone Joint Surg Am* 1993;75(2):249-258.
  50. Hawkins RJ, Angelo RL: Glenohumeral osteoarthritis: A late complication of the Putti-Platt repair. *J Bone Joint Surg Am* 1990;72(8):1193-1197.
  51. van der Zwaag HM, Brand R, Obermann WR, Rozing PM: Glenohumeral osteoarthritis after Putti-Platt repair. *J Shoulder Elbow Surg* 1999;8(3):252-258.
  52. Marx RG, McCarty EC, Montemurno TD, Altchek DW, Craig EV, Warren RF: Development of arthrosis following dislocation of the shoulder: A case-control study. *J Shoulder Elbow Surg* 2002;11(1):1-5.
  53. McCarty LP III, Cole BJ: Nonarthroplasty treatment of glenohumeral cartilage lesions. *Arthroscopy* 2005;21(9):1131-1142.
  54. Owens BD, Nelson BJ, Duffey ML, et al: Pathoanatomy of first-time, traumatic, anterior glenohumeral subluxation events. *J Bone Joint Surg Am* 2010;92(7):1605-1611.
  55. Buscayret F, Edwards TB, Szabo I, Adeleine P, Coudane H, Walch G: Glenohumeral arthrosis in anterior instability before and after surgical treatment: Incidence and contributing factors. *Am J Sports Med* 2004;32(5):1165-1172.
  56. Neviasser TJ: The GLAD lesion: Another cause of anterior shoulder pain. *Arthroscopy* 1993;9(1):22-23.
  57. Arlet JF, Ficat P, Lartigue G: Mode of onset of primary osteonecrosis of the femoral head. (Stage I. Uncomplicated). Study of 20 cases histologically verified by punch biopsy. *Rev Rhum Mal Osteoartic* 1968;35(5):239-249.