

# A Biomechanical Analysis of Anterior Bankart Repair Using Suture Anchors

Shane J. Nho,\* MD, MS, Rachel M. Frank,\* BS, Geoffrey S. Van Thiel,\* MD, MBA, Fan Chia Wang,\*† MS, Vincent M. Wang,\* PhD, LCDR Matthew T. Provencher,‡ MD MC USNR, and Nikhil N. Verma,\*§ MD

From the \*Department of Orthopaedic Surgery, Rush University Medical Center, Chicago, Illinois, the †Department of Bioengineering, University of Illinois at Chicago, Chicago, Illinois, and the ‡Department of Orthopaedic Surgery, Naval Medical Center, San Diego, California

**Background:** Arthroscopic repair of anterior Bankart lesions is typically done with single-loaded suture anchors tied with simple stitch configuration.

**Hypothesis:** The knotless suture anchor will have similar biomechanical properties compared with two types of conventional suture anchors.

**Study Design:** Controlled laboratory study.

**Methods:** Fresh-frozen shoulders were dissected and an anteroinferior Bankart lesion was created. For phase 1, specimens were randomized into either simple stitch (SSA) or knotless suture anchors (KSA) and loaded to failure. For phase 2, specimens were randomized into 1 of 4 repair techniques and cyclically loaded then loaded to failure: (1) SSA, (2) suture anchor with horizontal mattress configuration, (3) double-loaded suture anchor with simple stitch configuration, or (4) KSA. Data recorded included mode of failure, ultimate load to failure, load at 2 mm of displacement, as well as displacement during cyclical loading.

**Results:** For phase 1, the load required to 2 mm displacement of the repair construct was significantly greater in SSA ( $66.5 \pm 21.7$  N) than KSA ( $35.0 \pm 12.5$  N,  $P = .02$ ). For phase 2, there was a statistically significant difference in ultimate load to failure among the 4 groups, with both the single-loaded suture anchor with simple stitch ( $184.0 \pm 64.5$  N), horizontal mattress stitch ( $189.0 \pm 65.3$  N), and double-loaded suture anchor with simple stitch ( $216.7 \pm 61.7$  N) groups having significantly ( $P < .05$ ) higher loads than the knotless group ( $103.9 \pm 52.8$  N). There was no statistically significant difference ( $P > .05$ ) among the 4 groups in displacement after cyclical loading or load at 2 mm of displacement.

**Conclusion:** Both knotless and simple anchor configurations demonstrated similar single loads to failure (without cycling); however, the knotless device required less single load to displace 2 mm. All repair stitches, including simple, horizontal, and double-loaded performed similarly.

**Clinical Relevance:** The findings may suggest that with cyclical loading up to 25 N there is no difference in gapping greater than 2 mm, but a macrotraumatic event may demonstrate a difference in fixation during the initial postoperative period. Additional in vivo studies are needed to determine whether these differences affect the integrity of the repair construct and, ultimately, the clinical outcome.

**Keywords:** plication; glenohumeral joint; Bankart; knotless; suture anchor

Anterior shoulder instability remains a growing problem, especially in the young athletic population. Throughout

§Address correspondence to Nikhil N. Verma, MD, Rush University Medical Center, 1725 West Harrison Street, Suite 1063, Chicago, IL 60612 (e-mail: nverma@rushortho.com).

Presented at the 35th annual meeting of the AOSSM, Keystone, Colorado, July 2009.

The authors declared that they had no conflicts of interests in their authorship and publication of this contribution.

the last decade, all-arthroscopic techniques have become an accepted method of performing shoulder stabilization procedures.<sup>4,14-16,20,32,33</sup> Typically, in most episodes of traumatic glenohumeral instability, tearing of the labrum occurs, requiring repair of the torn tissue to the glenoid rim with suture anchors. In addition, it has been shown that capsular injury in combination with labral tear is required before instability occurs. Several methods of capsulolabral repair fixation have been described, including use of glenoid bone anchors with capsular plication. A number of different suture anchor repair constructs have been described, but there is no consensus regarding the optimal biomechanical construct. Additionally, there has

been recent interest in knotless suture anchor fixation in shoulder arthroscopy, and some surgeons have begun applying knotless anchors for Bankart repairs. Knotless fixation devices have potential advantages because (1) they are relatively easy to use, obviating the need for an arthroscopic knot; (2) they are more efficient; and (3) they diminish the potential risk of knot abrasion within the glenohumeral joint.

The purpose of the present study was to determine the biomechanical stability (as determined by several biomechanical testing parameters) of an anterior Bankart repair with capsular plication performed with glenoid bone anchors using several different suture plication techniques. The specific aims of the study were (1) to compare the biomechanical properties of single-loaded suture anchors with simple stitch configuration to knotless suture anchors (no stitch) *without* cyclical loading and (2) to compare the biomechanical properties *with* cyclical loading of single-loaded suture anchors with simple stitch configuration, single-loaded suture anchors with horizontal mattress stitch configuration, double-loaded suture anchors with simple stitch configuration, and knotless suture anchors (no stitch). Our null hypothesis was that there would be no biomechanical differences between the different repair constructs.

## MATERIALS AND METHODS

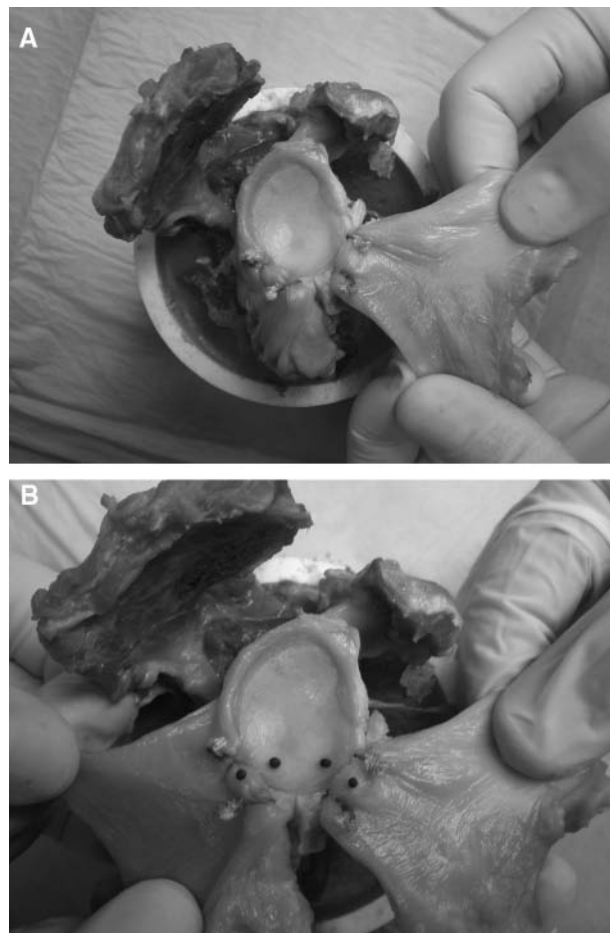
A total of 30 fresh-frozen human cadaveric shoulders were used for this study (10 in phase 1; 20 in phase 2). After all soft tissues were dissected, the humeral head was disarticulated from the glenoid via careful dissection of the capsular tissue from its most lateral insertion on the humerus, thereby preserving as much capsular tissue as possible. Each glenoid was then visually inspected. Exclusion criteria were (1) significant degenerative changes, (2) any absent labral tissue, and (3) labral damage to the inferior quadrants including cracks, splitting, fissures, or any other incompetence; however, no specimens met the criteria for exclusion. To assess the potential influence of bone density, each specimen also underwent dual-energy x-ray absorptiometry (DEXA) bone density testing with a bone densitometer at the region of the bone intended for fixation as well as at the anatomical neck of the humerus.

For all specimens, the glenoid capsulolabral complex was divided into quadrants, with the focus on the antero-inferior (AI) quadrant. The AI quadrant was defined as the inferior half of the glenoid from 3 o'clock to 6 o'clock (right shoulder) with the 6-o'clock position separating the AI quadrant from the posteroinferior quadrant. The position of interest was thus from 3 o'clock to 6 o'clock (right shoulder). Before repair, the specimens underwent a creation of a Bankart tear of the entire AI quadrant with a No. 15 scalpel, with the chondrolabral junction carefully elevated and the capsule medially dissected down to the glenoid neck.

For phase 1, a total of 10 fresh-frozen human cadaveric shoulders with a mean age of  $55 \pm 5$  years (range, 48-63) were thawed and dissected down to the glenohumeral

TABLE 1  
Specimen Properties—Phase 1

	Simple Stitch	Knotless	P Value
Age (years)	$55.2 \pm 2.6$	$54.0 \pm 6.1$	.72
Bone mineral density (g/cm <sup>2</sup> )	$0.65 \pm 0.16$	$0.64 \pm 0.17$	.95
Gender	M: 5/5 (100%)	M: 5/5 (100%)	
Side	L: 4/5 (80%) R: 1/5 (20%)	L: 1/5 (20%) R: 4/5 (80%)	



**Figure 1.** A, specimen preparation (a suture anchor with simple stitch configuration is shown); B, testing setup for digital motion analysis with black markers (a posteroinferior quadrant preparation is also shown).

capsule and labrum. There were 5 right shoulders and 5 left shoulders. All 10 specimens were from male donors (Table 1). Specimens were randomized by a computer to 1 of 2 groups: SSA, repaired with single-loaded suture anchors tied in simple stitch configuration (3.0 mm PEEK SutureTak, Arthrex, Inc, Naples, Florida); and KSA, repaired with knotless suture anchors (no stitch) (2.9 mm PEEK PushLock, Arthrex) (Figure 1).

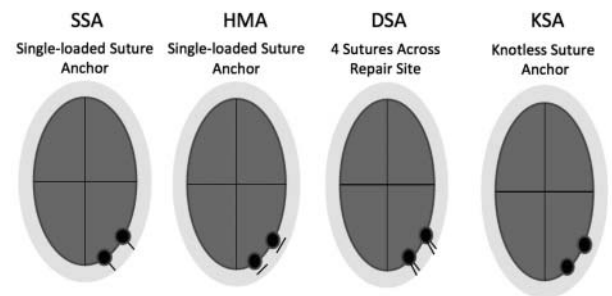
TABLE 2  
Specimen Properties—Phase 2<sup>a</sup>

	SSA	HSA	DSA	KSA	P Value
Age (years)	57.8 ± 13.6	59.0 ± 10.8	72.8 ± 13.0	71.6 ± 20.1	.30
Bone mineral density (g/cm <sup>2</sup> )	0.61 ± 0.1	0.67 ± 0.1	0.55 ± 0.1	0.59 ± 0.2	.52
Gender	M: 2/5 (40%)	M: 4/5 (80%)	M: 4/5 (80%)	M: 0/5 (0%)	
	F: 3/5 (60%)	F: 1/5 (20%)	F: 1/5 (20%)	F: 5/5 (100%)	
Side	L: 2/5 (40%)	L: 4/5 (80%)	L: 1/5 (20%)	L: 3/5 (60%)	
	R: 3/5 (60%)	R: 1/5 (20%)	R: 4/5 (80%)	R: 2/5 (40%)	

<sup>a</sup>SSA, single-loaded suture anchors; HSA, single-loaded suture anchors tied in a horizontal mattress configuration; DSA, double-loaded suture anchors tied in a simple stitch configuration; KSA, knotless bone anchors.

For phase 2, a total of 20 fresh-frozen human cadaveric shoulders with a mean age of 64 ± 15 years (range, 45-91) were thawed and dissected down to the glenohumeral capsule and labrum. There were 10 right shoulders and 10 left shoulders. Ten shoulders were from male donors and 10 were from female donors (Table 2). The specimens were randomized by a computer to 1 of 4 repair groups: SSA, repair with single-loaded suture anchors tied in simple stitch configuration (3.0 mm PEEK SutureTak, Arthrex); HSA, repair with single-loaded suture anchors tied in horizontal mattress configuration (3.0 mm PEEK SutureTak, Arthrex); DSA, repair with double-loaded suture anchors tied in simple stitch configuration (3.0 mm PEEK SutureTak, Arthrex); and KSA, repair with knotless bone anchors (no stitch) (2.9 mm PEEK PushLock, Arthrex).

For each specimen, 2 suture anchors were positioned at 4 o'clock and 5 o'clock. For the SSA repair, the drill for the 3-mm SutureTak was used with the drill guide positioned over the glenoid rim, and the suture anchor was inserted to the second laser line. A 45°-suture lasso (Arthrex) was inserted in the anterior capsule 10 mm from the capsulolabral junction using a 5:30 position for the 5:00-o'clock anchor and 4:30 for the 4-o'clock anchor. The suture lasso was directed so that the tip exited at the labral-articular surface interface within the Bankart defect, and the nitinol wire was advanced. A No. 2 FiberWire (Arthrex) suture from the suture anchor was placed in the nitinol wire loop from the articular side and passed through the capsulolabral tissue to exit on the capsular side. The capsulolabral tissue was repaired with a simple stitch configuration and tied with reverse half-hitches on alternating posts (RHAP). For HSA, both suture limbs were passed from the articular side to the capsular side using the 45°-suture lasso, and a horizontal mattress stitch was tied with RHAP. The 2 suture limbs were spaced 3 mm apart. For DSA, another No. 2 FiberWire suture was passed through the eyelet to create a double-loaded suture anchor. The technique was identical to that of group 1, but the second No. 2 FiberWire was also passed through the capsulolabral tissue with the 2 limbs spaced by 3 mm. Both sutures were tied with simple stitch configuration using RHAP. For the KSA, the suture was passed through the anterior capsule 10 mm from the capsulolabral junction using a 5:30 position for the 5:00-o'clock anchor and 4:30 for the 4-o'clock anchor using a 45°-suture lasso.



**Figure 2.** Comparison of specimens repaired with single-loaded suture anchors tied in simple stitch configuration (SSA), single-loaded suture anchors tied in horizontal mattress stitch configuration (HMA), double-loaded suture anchors tied in simple stitch configuration (DSA), and repair with knotless bone anchors (no stitch) (KSA).

Using the nitinol wire, a free FiberWire suture was passed from the articular side to the capsular side. A drill for the 2.9-mm PushLock was used over the drill guide. The free ends of the FiberWire suture were passed through the eyelet of the knotless suture anchor, and the knotless suture anchor was advanced into the glenoid while tension was maintained on the suture ends. Once the anchor body made contact with the glenoid bone, the button on the proximal end of the anchor handle was tapped to the appropriate depth and deployed (Figure 2).

After repair, in both phase 1 and phase 2 of the study, the glenoid was separated from the remainder of the scapula by sawing from 1 cm below the infraglenoid ridge along the infraspinatus fossa in a medial direction, cutting along the medial border of the scapula just under the spine. Each specimen was then potted in dental acrylic (Isocryl, Lang Dental, Wheeling, Illinois) so that the glenoid fossa was parallel with the surface of the potting container. After the specimen was potted, the capsular tissue was cut with a scalpel at the 3-o'clock and 6-o'clock positions to isolate the AI quadrant. Two specific diameter markers were placed on the surface of the specimen to facilitate optical tracking of labral and/or capsular tissue during testing, with one marker on the surface of the glenoid and the other marker 1 cm away on the surface of the labrum between the 2

TABLE 3  
Results—Phase 1

	Simple Stitch	Knotless	P Value
Ultimate load to failure (N)	173.1 ± 45.3	167.9 ± 42.3	.86
Load at 2 mm displacement (N)	66.5 ± 21.7	35.0 ± 12.5	.02
Stiffness (N/mm)	23.3 ± 4.7	28.2 ± 10.3	.36
Method of failure	Anchor: 2/5 (40%) Capsule: 3/5 (60%)	Anchor: 1/5 (20%) Capsule: 4/5 (80%)	.49

sutures (Figure 1B). Digital calipers were used to ensure consistent placement of the markers among specimens.

The specimen was then loaded onto a materials testing system (MTS Insight 5, MTS Systems Corp, Eden Prairie, Minnesota) for biomechanical testing. The potted glenoid was placed in a custom-made, adjustable jig that was fixed to the platform of the MTS. The repaired AI quadrant was placed in a custom soft tissue clamp, attached to an in-line 1000-N load cell on the MTS. The clamp gripped the specimen 1.5 cm above the marker on the labrum, again measured with digital calipers to ensure consistent gripping among specimens. The specimen was oriented so that the vector of labral translation force was directed away from the glenoid in an anteroinferior direction, in a “worst-case” vector (0°). A 1-megapixel digital video camera was used to optically track the marker displacements throughout testing.<sup>12</sup> The video data (48 frames per second) were analyzed with Digital Motion Analysis Software (Spica Technology Corporation, Maui, Hawaii) and were synchronized to the load and actuator displacement data recorded by the MTS software. On the basis of our calibration studies of marker displacements similar to those seen in the present study, the measurement precision and accuracy of our optical imaging system was 3 μm and 60 μm, respectively. Based on previous studies<sup>27,29</sup> and our own pilot data, the following testing conditions were used for each specimen: phase 1: preload at 5 N (constant load) for 2 minutes followed by pull to failure at 15 mm/min; phase 2: preload at 5 N (constant load) for 2 minutes, followed by cyclical loading for 100 cycles from 5 to 25 N at 1 Hz, followed by pulling to failure load at 15 mm/min.

Data analyzed included mode of failure, ultimate load to failure, load at 2 mm of tissue displacement, as well as tissue displacement during cyclical loading (during the entire 100 cycles and during the final cycle only). Stiffness was calculated as the steepest slope of the load-displacement curve spanning 30% of the data points collected between initiation of the load-to-failure test and the maximum load. For tissue displacement analyses, using the optical tracking software, a segment was defined as the shortest distance between the 2 surface markers. From the cyclical test, 2 primary parameters were quantified, including *cyclic elongation*, defined as the relative increase in segment length from the peak load of the first cycle to the peak load of the final cycle of testing, and *elongation amplitude*, defined as the peak to valley measurement of the segment elongation for the final test cycle. Load at 2 mm of tissue (optical) displacement as well as ultimate load to failure were determined via the synchronized

digital motion analysis software and MTS data from the pull-to-failure test. After failure occurred, the failure mode was determined (eg, anchor pullout, suture tear, tear at glenolabral junction, tear at capsulolabral tissue)

Unpaired *t* tests for phase 1 and 1-way analysis of variance with Tukey’s post hoc testing for phase 2 were used to analyze the different groups using SPSS statistical software (SPSS Science Inc, Chicago, Illinois), with statistical significance at  $P < .05$ . Chi-square testing was used to analyze modes of failure between the testing groups, with statistical significance at  $P < .05$ .

## RESULTS

### Phase 1

The ultimate load to failure in the SSA and KSA groups was  $173.1 \pm 45.3$  N and  $167.9 \pm 42.3$  N, respectively (percent change = 3%), which was not statistically significant ( $P = .86$ ). The SSA group required a load of  $66.5 \pm 21.7$  N to reach 2 mm of displacement during failure testing compared with  $35.0 \pm 12.5$  N in the KSA group ( $P = .02$ ). There was no significant difference ( $P > .05$ ) in the stiffness (N/mm) during ultimate load to failure between the 2 groups (Table 3).

The modes of failure did not differ significantly between the 2 groups ( $P = .49$ ). In the SSA group, failure occurred by anchor pullout in 2 specimens (40%), while capsular rupture was responsible for 3 failures (60%). In the KSA group, failure occurred by anchor pullout in 1 specimen (20%), whereas capsule rupture accounted for the remaining 4 specimens (80%).

There was no significant difference in age ( $P = .72$ ) or mean bone mineral density between the 2 groups of shoulder specimens ( $P = .95$ ) (Table 1).

### Phase 2

There was a statistically significant difference in ultimate load to failure among the 4 groups ( $P < .05$ ). Specifically, the single-loaded suture anchor with simple stitch ( $184.0 \pm 64.5$  N), horizontal mattress ( $189.6 \pm 65.3$  N), and double-loaded suture anchor with simple stitch ( $216.7 \pm 61.7$  N) groups had significantly ( $P = .03$ ,  $P = .03$ ,  $P = .01$ ) higher loads to failure than the knotless group ( $103.9 \pm 52.8$  N). There was no difference among ultimate load to failure between the simple, horizontal mattress, and double-loaded groups. There was no statistical difference among any of the

TABLE 4  
Results—Phase 2<sup>a</sup>

	SSA	HSA	DSA	KSA	P Value
Ultimate load to failure (N)	184.0 ± 64.5	189.0 ± 65.3	216.7 ± 61.7	103.9 ± 52.8	<.05 SSA vs KSA: =.03 HMA vs KSA: =.03 DSA vs KSA: =.01
Load at 2 mm displacement (N)	50.0 ± 17.8	81.7 ± 32.3	64.0 ± 12.2	60.5 ± 23.5	>.05
Stiffness (N/mm)	35.1 ± 5.7	62.1 ± 47.6	35.6 ± 7.6	39.4 ± 14.1	>.05
Cyclic elongation (mm)	0.70 ± 0.53	0.52 ± 0.62	1.11 ± 0.77	1.00 ± 0.41	>.05
Elongation amplitude (of final cycle) (mm)	0.41 ± 0.16	0.47 ± 0.26	0.58 ± 0.18	0.43 ± 0.10	>.05
Method of failure	Anchor: 5/5 (100%)	Glenolabral: 4/5 (80%) Capsule: 1/5 (20%)	Anchor: 3/5 (60%) Glenolabral: 1/5 (20%) Capsule: 1/5 (20%)	Anchor: 3/5 (60%) Capsule: 2/5 (40%)	=.018

<sup>a</sup>SSA, single-loaded suture anchors; HSA, single-loaded suture anchors tied in a horizontal mattress configuration; DSA, double-loaded suture anchors tied in a simple stitch configuration; KSA, knotless bone anchors.

groups when considering load at 2 mm of displacement ( $P = .21$ ). There was also no significant difference ( $P = .31$ ) in the stiffness (N/mm) among the 4 groups (Table 4).

After cyclical loading, there was no statistically significant difference in gapping (elongation) of the repair construct among the 4 groups ( $P > .05$ ), nor was there a statistically significant difference ( $P > .05$ ) in the gapping of the final cycle (of 100).

There was no significant difference in age ( $P = .30$ ) or average bone mineral density ( $P = .52$ ) between the 3 groups of shoulder specimens, as indicated in Table 2. No specimens failed during the cyclical loading portion of the test protocol.

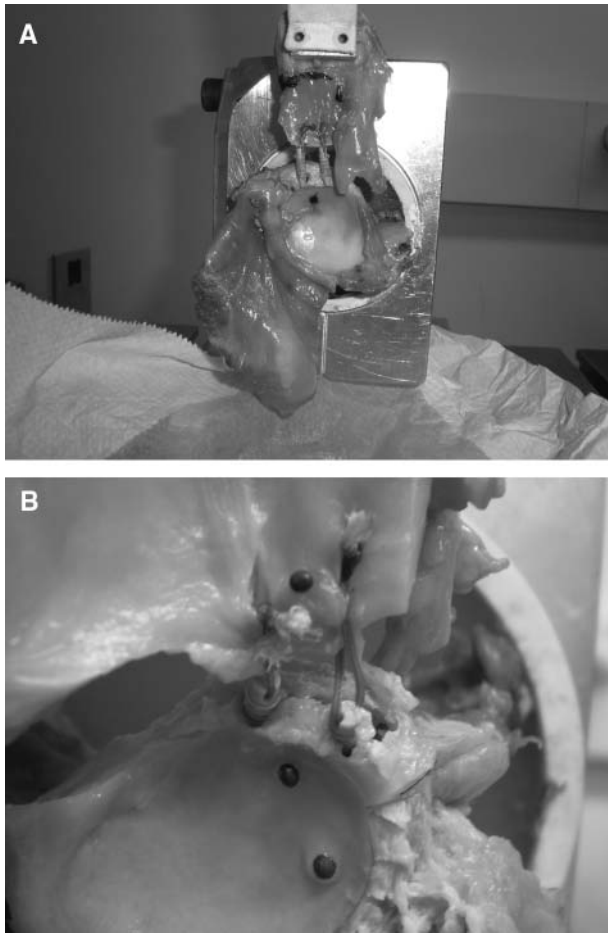
The modes of failure differed significantly ( $P = .018$ ) among the 4 groups, as shown in Table 4. In the simple stitch group, failure occurred by anchor pullout in all 5 specimens (100%). In the horizontal mattress group, failure occurred at the glenolabral junction in 4 specimens (80%) and via capsule rupture in 1 specimen (20%). In the double-loaded group, failure occurred by anchor pullout in 3 specimens (60%), at the glenolabral junction in 1 specimen (20%), and via capsule rupture in 1 specimen (20%). Finally, in the knotless group, failure occurred by anchor pullout in 3 specimens (60%), whereas capsule rupture accounted for the remaining 2 specimens (40%) (Figure 3).

## DISCUSSION

The treatment of anterior shoulder instability continues to evolve with development of new techniques and fixation devices. In this study, the biomechanical properties of several different repair constructs for the fixation of the AI quadrant of the glenoid capsule were compared. Although there are several biomechanical studies describing properties of repair constructs for anterior shoulder instability repair, to our knowledge, this is the first study to directly compare 4 specific techniques in terms of both ultimate load to failure and cyclical loading.

Knotless suture anchors have been thought to provide a more consistent, faster, and easier device for tendon-to-bone fixation and have become available for use for labral repair and rotator cuff repair. The findings of the present study demonstrate that the performance of conventional suture anchors and knotless suture anchors were similar in terms of ultimate load to failure without cyclical loading; however, there were significant differences between load required to reach 2 mm of displacement. In addition, the findings of the present study demonstrate that the ultimate strength values of all 3 suture anchor stitch configurations were greater than that of the knotless suture anchors after cyclical loading; however, all 4 repair constructs performed similarly in terms of load required to reach 2 mm displacement and elongation during cyclical loading.

Techniques using knotless suture anchors were introduced to address some of the issues associated with arthroscopic knot tying that might be responsible for recurrent instability, including difficulty with knot tensioning and difficulty with tying the knot itself. Additionally, the elimination of the knot itself may minimize risk of injury to the articular surface. Clinical failure of arthroscopic knots has been described at approximately 3 mm of displacement of the repair construct, and labral insufficiency has been noted to be a cause of revision shoulder stabilization.<sup>6,18</sup> Thus, the higher load sustained at 2 mm of displacement by the specimens fixed with simple stitch configuration potentially indicates a repair that may be more resistant to loading during the initial postoperative period compared with the knotless suture anchor repairs. Sileo et al<sup>31</sup> published a biomechanical study comparing the conventional bioabsorbable (Lupine, DePuy Mitek, Raynham, Massachusetts) and knotless suture anchors (Bio-Knotless, DePuy Mitek) for type II superior labrum, anterior and posterior repairs with mattress suture configurations. The authors reported that the conventional suture anchor demonstrated superior fixation strength in terms of ultimate load to failure, cycles to failure, load to 2-mm gapping, and cycles to 2-mm gapping compared with the knotless design.<sup>31</sup>



**Figure 3.** A, failure of repair by anchor pullout during pull-to-failure testing. B, close-up view of the anchors.

Most of the biomechanical and clinical studies on knotless suture anchors involve the Knotless (Mitek Products, Westwood, Massachusetts) or Bio-Knotless (DePuy Mitek) suture anchor that was modeled after the Mitek GII Anchor (Thal<sup>34-36</sup>). The proposed advantage of the knotless design was the ability to provide a consistent, secure, low-profile repair that does not require a bulky intra-articular knot.<sup>34</sup> The soft tissue tension could be altered depending on the depth of insertion. One of the differences between the design of the knotless suture anchor (PushLock) used in the present study was the ability to adjust the tension without having to increase the depth of insertion. A theoretical advantage was the ability to maintain fixation at the level of the subchondral bone with the PushLock designs as opposed to potentially deeper insertion with the Bio-Knotless designs in which the suture anchor would be fixed against cancellous bone. Brown et al<sup>5</sup> reported that there was a trend toward early failure with the Bio-Knotless RC suture anchor as 5 of 15 specimens had anchor pullout during the initial phases of cyclical loading. The authors hypothesized that the inherent design of the anchor predisposed it to gapping at lower loads because the anchor may be implanted deeper and

required abutment against the cortical bone before it was able to provide the strongest fixation.<sup>5</sup> Additional studies need to be performed to determine if there is a distinct advantage to tensioning the repaired soft tissue without increasing the insertion depth.

Clinically, knotless suture anchors have been reported to produce successful outcomes after shoulder stabilization surgery.<sup>11,13,37,40</sup> Thal et al<sup>37</sup> also published their experience and reported a recurrence rate of 6.9% using either Knotless or Bio-Knotless repairs of Bankart lesions. Kocaoglu et al<sup>19</sup> compared metallic suture anchors (3.5-mm metallic suture anchor, Arthrex) and knotless suture anchors (3.5-mm PEEK PushLock, Arthrex) in collision athletes. The authors reported that both groups demonstrated a significant improvement in Rowe scores, and only 1 patient in each group had a redislocation.<sup>8,19</sup> However, Cho et al<sup>8</sup> reported a redislocation rate of 23.8% in the knotless group compared with 4.9% in the knot-tying group, and the knotless group also demonstrated significantly worse scores in terms of pain and satisfaction.

The use of suture anchors in the arthroscopic treatment of anterior shoulder instability has been well described both biomechanically<sup>2,3,24,25,27,29,39</sup> and clinically.<sup>11</sup> The techniques used vary considerably among surgeons and institutions, and thus a comparison of differing suture techniques is difficult. Arthroscopic knot-tying techniques and configurations have been studied extensively.<sup>9,10,21,22,30</sup> In the present study, biomechanical loads *without* cycling demonstrated that KSA required lower loads to reach 2 mm of gapping than SSA fixation with simple stitch configuration, but there was no difference in ultimate load to failure. When cyclical loading was followed by loading to failure, there were no differences in terms of gapping between all 4 groups, but the KSA demonstrated significantly lower ultimate load to failure compared with the groups that required knots. Interestingly, the mean ultimate load to failure for SSA with simple stitch was  $173.1 \pm 45.3$  N without cycling and  $184.0 \pm 64.5$  N with cycling, whereas the KSA demonstrated a mean ultimate load to failure of  $167.9 \pm 42.3$  N without cycling and  $103.9 \pm 52.8$  N with cycling. Taken together, the findings suggest that the SSA is able to maintain fixation strength, but the KSA appears to have slippage after cycling. The difference between KSA fixation and knot-tied suture anchors used in the present study is that the KSA requires interference of the suture to maintain the fixation and tension of the soft tissue to bone. Perhaps the suture material within the prepared drill hole decreases the friction between the anchor and the surrounding bone compared with the standard anchors. These findings only demonstrate the initial fixation strength and do not take into account biologic healing of the capsule to osseous glenoid rim.

There were several limitations to this study. As with any cadaveric study, this was a time zero *in vitro* analysis and there was no opportunity for capsular tissues to heal

<sup>||</sup>References 7, 8, 11, 13, 17, 23, 26, 37, 38

after the plication. Because both the time and method of healing that occurs between the tissues after plication, as well as the repair construct fixation strength needed to allow for early postoperative rehabilitation are unknown, the results from this study may differ from what occurs in an in vivo setting. Although there were no differences in terms of age, gender, and BMD, the specimens were not matched pairs for Phase 1 of the study. In Phase 2 of the study, there were also no differences in terms of age and BMD, but there were 5 of 5 female specimens in the KSA group compared with 3 of 5 in the SSA, 1 of 5 in the HMA, and 1 of 5 in the DL groups. The role of age, gender, and BMD on capsular tissue quality is not known, but there are no other measures of soft tissue quality to our knowledge. Also, the capsular tissue in each specimen was not stretched before testing, and it is possible that more laxity may better replicate clinical situations. The testing setup did not incorporate a dynamic loading model, and no dynamic muscles were included, which are the most important dynamic stabilizers of the joint. In addition, despite visually inspecting each specimen to ensure that it was free of glenohumeral disease, it is impossible to know if the specimens had any history of instability. To minimize the effects of age on blood supply and degeneration to the glenoid,<sup>1,28</sup> cadavers with a relatively young mean age were included in this study.

There were many strengths of the present study. There were no differences in terms of age, bone mineral density, and capsular tissue thickness. The repairs only differed by the suture configuration, and all repairs were performed using the same instruments, suture material, and arthroscopic knot-tying technique, with the same orthopaedic surgeon. The biomechanical protocol has been used and published in previous studies by our group and other laboratories,<sup>29</sup> and optical tracking was also used to more accurately measure displacement. The biomechanical testing parameter was performed with cyclical loading to replicate clinical conditions akin to a postoperative situation.

## CONCLUSION

In the present study, we reported that the SSA required greater loads to reach 2-mm gapping than KSA without cyclical loading. We also determined that there was a significant difference between suture anchor repair with simple stitch (SSA and DSA) and horizontal mattress (HAS) compared with KSA in terms of ultimate load to failure with cyclical loading. However, there were no statistically significant differences between groups in terms of 2 mm of displacement with cyclical loading which may be more clinically relevant than ultimate load to failure. The findings may suggest that with cyclical loading up to 25 N, there is no difference in gapping greater than 2 mm, but a macrotraumatic event may demonstrate a difference in fixation during the initial postoperative period. Additional in vivo studies are needed to determine whether these differences affect the integrity of the repair construct, and ultimately, the clinical outcome.

## REFERENCES

- Andary JL, Petersen SA. The vascular anatomy of the glenohumeral capsule and ligaments: an anatomic study. *J Bone Joint Surg Am*. 2002;84(12):2258-2265.
- Barber FA, Coons DA, Ruiz-Suarez M. Cyclic load testing of biodegradable suture anchors containing 2 high-strength sutures. *Arthroscopy*. 2007;23(4):355-360.
- Barber FA, Coons DA, Ruiz-Suarez M. Cyclic load testing and ultimate failure strength of biodegradable glenoid anchors. *Arthroscopy*. 2008;24(2):224-228.
- Bottoni CR, Franks BR, Moore JH, DeBerardino TM, Taylor DC, Arciero RA. Operative stabilization of posterior shoulder instability. *Am J Sports Med*. 2005;33(7):996-1002.
- Brown BS, Cooper AD, McIlff TE, Key VH, Toby EB. Initial fixation and cyclic loading stability of knotless suture anchors for rotator cuff repair. *J Shoulder Elbow Surg*. 2008;17(2):313-318.
- Burkhart SS, Wirth MA, Simonich M, Salem D, Lancot D, Athanasiou K. Knot security in simple sliding knots and its relationship to rotator cuff repair: how secure must the knot be? *Arthroscopy*. 2000;16(2):202-207.
- Carreira DS, Mazzocca AD, Oryhon J, Brown FM, Hayden JK, Romeo AA. A prospective outcome evaluation of arthroscopic Bankart repairs: minimum 2-year follow-up. *Am J Sports Med*. 2006;34(5):771-777.
- Cho NS, Lubis AM, Ha JH, Rhee YG. Clinical results of arthroscopic Bankart repair with knot-tying and knotless suture anchors. *Arthroscopy*. 2006;22(12):1276-1282.
- Elkousy H, Hammerman SM, Edwards TB, et al. The arthroscopic square knot: a biomechanical comparison with open and arthroscopic knots. *Arthroscopy*. 2006;22(7):736-741.
- Elkousy HA, Sekiya JK, Stabile KJ, McMahon PJ. A biomechanical comparison of arthroscopic sliding and sliding-locking knots. *Arthroscopy*. 2005;21(2):204-210.
- Garofalo R, Mocchi A, Moretti B, et al. Arthroscopic treatment of anterior shoulder instability using knotless suture anchors. *Arthroscopy*. 2005;21(11):1283-1289.
- Gupta A, Lattermann C, Busam M, Riff A, Bach BR Jr, Wang VM. Biomechanical evaluation of bioabsorbable versus metallic screws for posterior cruciate ligament inlay graft fixation: a comparative study. *Am J Sports Med*. 2009;37(4):748-753.
- Hayashida K, Yoneda M, Mizuno N, Fukushima S, Nakagawa S. Arthroscopic Bankart repair with knotless suture anchor for traumatic anterior shoulder instability: results of short-term follow-up. *Arthroscopy*. 2006;22(6):620-626.
- Hiemstra LA, Sasyniuk TM, Mohtadi NG, Fick GH. Shoulder strength after open versus arthroscopic stabilization. *Am J Sports Med*. 2008;36(5):861-867.
- Hubbell JD, Ahmad S, Bezenoff LS, Fond J, Petrone FA. Comparison of shoulder stabilization using arthroscopic transglenoid sutures versus open capsulolabral repairs: a 5-year minimum follow-up. *Am J Sports Med*. 2004;32(3):650-654.
- Kakar S, Voloshin I, Kaye EK, et al. Posterior shoulder instability: comprehensive analysis of open and arthroscopic approaches. *Am J Orthop*. 2007;36(12):655-659.
- Kim SH, Ha KI, Kim YM. Arthroscopic revision Bankart repair: a prospective outcome study. *Arthroscopy*. 2002;18(5):469-482.
- Kim SH, Ha KI, Yoo JC, Noh KC. Kim's lesion: an incomplete and concealed avulsion of the posteroinferior labrum in posterior or multidirectional posteroinferior instability of the shoulder. *Arthroscopy*. 2004;20(7):712-720.
- Kocaoglu B, Guven O, Nalbantoglu U, Aydin N, Haklar U. No difference between knotless sutures and suture anchors in arthroscopic repair of Bankart lesions in collision athletes. *Knee Surg Sports Traumatol Arthrosc*. 2009;17(7):844-849.
- Kropf EJ, Tjoumakaris FP, Sekiya JK. Arthroscopic shoulder stabilization: is there ever a need to open? *Arthroscopy*. 2007;23(7):779-784.

21. Lo IK, Burkhart SS, Chan KC, Athanasiou K. Arthroscopic knots: determining the optimal balance of loop security and knot security. *Arthroscopy*. 2004;20(5):489-502.
22. Mahar AT, Moezzi DM, Serra-Hsu F, Pedowitz RA. Comparison and performance characteristics of 3 different knots when tied with 2 suture materials used for shoulder arthroscopy. *Arthroscopy*. 2006;22(6):614 e611-612.
23. Mazzocca AD, Brown FM Jr, Carreira DS, Hayden J, Romeo AA. Arthroscopic anterior shoulder stabilization of collision and contact athletes. *Am J Sports Med*. 2005;33(1):52-60.
24. McFarland EG, Park HB, Keyurapan E, Gill HS, Selhi HS. Suture anchors and tacks for shoulder surgery, Part 1: biology and biomechanics. *Am J Sports Med*. 2005;33(12):1918-1923.
25. Mohammed KD, Sonnabend DH, Goldberg JA, Hutabarat S, Walker P, Walsh WR. Biomechanical performance of Bankart repairs in a human cadaveric shoulder model. *Am J Sports Med*. 1998;26(6):831-835.
26. Mologne TS, Provencher MT, Menzel KA, Vachon TA, Dewing CB. Arthroscopic stabilization in patients with an inverted pear glenoid: results in patients with bone loss of the anterior glenoid. *Am J Sports Med*. 2007;35(8):1276-1283.
27. Mueller MB, Fredrich HH, Steinhäuser E, Schreiber U, Arians A, Imhoff AB. Biomechanical evaluation of different suture anchors for the stabilization of anterior labrum lesions. *Arthroscopy*. 2005;21(5):611-619.
28. Prodromos CC, Ferry JA, Schiller AL, Zarins B. Histological studies of the glenoid labrum from fetal life to old age. *J Bone Joint Surg Am*. 1990;72(9):1344-1348.
29. Provencher MT, Verma N, Obopilwe E, et al. A biomechanical analysis of capsular plication versus anchor repair of the shoulder: can the labrum be used as a suture anchor? *Arthroscopy*. 2008;24(2):210-216.
30. Shah MR, Strauss EJ, Kaplan K, Jazrawi L, Rosen J. Initial loop and knot security of arthroscopic knots using high-strength sutures. *Arthroscopy*. 2007;23(8):884-888.
31. Sileo MJ, Lee SJ, Kremenich IJ, et al. Biomechanical comparison of a knotless suture anchor with standard suture anchor in the repair of type II SLAP tears. *Arthroscopy*. 2009;25(4):348-354.
32. Steinbeck J, Jerosch J. Arthroscopic transglenoid stabilization versus open anchor suturing in traumatic anterior instability of the shoulder. *Am J Sports Med*. 1998;26(3):373-378.
33. Steinbeck J, Witt KA, Marquardt B. Arthroscopic versus open anterior shoulder stabilization: a systematic validation [in German]. *Orthopäde*. 2009;38(1):36-40.
34. Thal R. A knotless suture anchor: technique for use in arthroscopic Bankart repair. *Arthroscopy*. 2001;17(2):213-218.
35. Thal R. A knotless suture anchor: design, function, and biomechanical testing. *Am J Sports Med*. 2001;29(5):646-649.
36. Thal R. Knotless suture anchor: arthroscopic Bankart repair without tying knots. *Clin Orthop Relat Res*. 2001;390:42-51.
37. Thal R, Nofziger M, Bridges M, Kim JJ. Arthroscopic Bankart repair using knotless or bioknotless suture anchors: 2- to 7-year results. *Arthroscopy*. 2007;23(4):367-375.
38. Westerheide KJ, Dopirak RM, Snyder SJ. Arthroscopic anterior stabilization and posterior capsular plication for anterior glenohumeral instability: a report of 71 cases. *Arthroscopy*. 2006;22(5):539-547.
39. Wetzler MJ, Bartolozzi AR, Gillespie MJ, et al. Fatigue properties of suture anchors in anterior shoulder reconstructions: Mitek GII. *Arthroscopy*. 1996;12(6):687-693.
40. Yian E, Wang C, Millett PJ, Warner JJ. Arthroscopic repair of SLAP lesions with a bioknotless suture anchor. *Arthroscopy*. 2004;20(5):547-551.