

# EFFECTS OF SERIAL SECTIONING AND REPAIR OF RADIAL TEARS IN THE LATERAL MENISCUS

GEOFFREY S. VAN THIEL, MD/MBA  
ROCKFORD ORTHOPEDIC ASSOCIATES, ROCKFORD, IL  
RUSH UNIVERSITY MEDICAL CENTER, CHICAGO, IL

GABRIELLE ODE, MD  
RUSH UNIVERSITY MEDICAL CENTER

BRIAN J. COLE, MD/MBA  
RUSH UNIVERSITY MEDICAL CENTER

**Background:** Radial transection of the peripheral fibers of the meniscus could render it non-functional; however, the biomechanical consequences of complete lateral meniscal radial tear and repair in human specimens has not been elucidated.

**Hypothesis:** Complete radial tear will exhibit knee contact mechanics approaching those of total meniscectomy. Repair of complete radial tears will recreate normal load transmission across the joint.

**Study Design:** Controlled laboratory study.

**Methods:** Five matched pairs of fresh-frozen human cadaveric knees were tested in axial compression (800N) at two knee flexion angles (0° and 60°). Six meniscal conditions were sequentially tested: (1) intact lateral meniscus, radial width tears of (2) 50%, (3) 75%, (4) 100%, (5) meniscal repair, and (6) total meniscectomy. Repairs were pair-matched and used either an inside-out or all-inside technique. Tekscan sensors measured tibiofemoral contact pressure (CP), peak contact force (PF), and contact area (CA) in the lateral meniscus and medial meniscus.

**Results:** Complete radial tear of the lateral meniscus produced significant increases in mean CP ( $p=0.0001$ ) and decreased CA ( $p<0.0001$ ) compared to the intact state. This effect was significantly less than that of total meniscectomy ( $p<0.0023$ ). Lesser degrees of radial tear were not significantly different from the intact state ( $p>0.3619$ ). Mean CP after either repair technique was not significantly different from the intact state ( $p=0.2595$ ) nor from each other ( $p=0.4000$ ). Meniscal repair produced an increase in CA compared with complete tear but was still significantly less than that of the intact meniscus ( $p<0.0001$ ). The medial compartment showed no significant difference between all testing conditions for 0° and 60° of flexion ( $p\geq 0.0650$ )

**Conclusion:** Complete radial meniscal tear of the lateral meniscus has a detrimental effect on load transmission. Repair improved contact area and pressure. Contact pressures for repaired menisci were not significantly different from the intact state. Biomechanical performance of repair constructs was equivalent.

**Clinical Relevance:** Repair of complete radial tear improves joint mechanics potentially decreasing the likelihood of cartilage degeneration.

**Key Words:** knee biomechanics; lateral meniscus; radial tear; meniscus repair

**What is known about this subject:** Previous studies have shown that partial radial tears of the medial meniscus result in significant increases in contact pressure relative to the intact meniscus, while also showing that partial meniscectomy significantly increases contact pressures compared to the intact state. There is limited knowledge, however, regarding the biomechanical effects of injury and repair of radial tears of the lateral meniscus.

**What this study adds to existing knowledge:** This study reports on the biomechanical effects of isolated partial or complete radial tears of the lateral meniscus, as well as repair of complete radial tears. Changes in contact biomechanics are quantified relative to the intact state as well as that of complete meniscectomy.

## INTRODUCTION

The majority of collagen fibers within the meniscus are circumferentially oriented. This orientation creates optimal resistance to hoop stresses, which displace the meniscus from the tibial plateau during weight bearing (7, 15). Negative outcomes following meniscectomy have been well documented with long term studies of meniscectomized knees demonstrating clinical and radiographic arthrosis (13, 18, 37). Several studies have noted greater incidence of arthrosis after lateral meniscectomy when compared to medial meniscectomy (2, 3, 18, 19). It has been suggested that a radially-oriented meniscal tear, which disrupts the primary, circumferential fibers of the meniscus, results in partial extrusion of the meniscus and abnormal load transmission equivalent to total meniscectomy (26, 33). Furthermore, it has been demonstrated that partial radial tears of the medial meniscus do not result in significant increases in contact pressure compared to the intact meniscus, while contact pressures following partial radial tears are also significantly lower than those seen after partial medial meniscectomy (8). It is presently unknown whether partial radial tears of the lateral meniscus behave similarly to partial radial tears of the medial meniscus. To our knowledge, however, there have been no studies that investigate the biomechanical effects of isolated partial or complete radial tears of the lateral meniscus.

Historically, treatment options for radial tear of the meniscus have been limited. While partial meniscectomy (21) has been the mainstay of treatment for radial tears, recently,

successful management with inside-out repair and all-inside repair of partial radial tears of the lateral meniscus has been reported (8, 10). Whether similar results can be expected for complete tears of the lateral meniscus is presently unknown.

The purpose of the current study was to establish the pattern of biomechanical changes that transpire in the medial and lateral compartments after serial radial transection of the lateral meniscus. Our primary objective was to describe the alteration in load transmission and contact area in the lateral tibiofemoral compartment resulting from varying degrees of radial meniscal tear using a human cadaveric model. Furthermore, repair of complete radial meniscal tear was studied to determine whether normal load transmission and contact area would be restored. Finally, inside-out and all-inside meniscal repair techniques were compared.

The hypotheses of this study were that (1) radial meniscal tear result in disruption of meniscal function with decreased tibiofemoral contact area and increased contact pressure, (2) changes in contact area and pressure after complete radial meniscal tear approach those of total meniscectomy, (3) both repair techniques of the complete radial tear recreate normal load transmission across the lateral hemi-joint, and exhibit similar contact mechanics to the intact meniscus.

## MATERIALS AND METHODS

### Specimen Preparation

Five matched pairs of fresh-frozen cadaveric knees from 1 female and 4 male donors were obtained from a tissue bank. The average age at time of death was 65 (range 50 to 82 years). Approval for use of cadaver specimens was granted by our institutional review board. All specimens were inspected to ensure they did not meet criteria for exclusion including deficient ligamentous structures, medial or lateral meniscal tears or evidence of previous knee surgery. Each knee was first thawed at room temperature overnight, followed by removal of skin, subcutaneous tissue and muscle with the exception of the popliteus, and the extensor mechanism. The tibia and femur were both transected approximately 13 cm from the joint line. Care was taken to preserve the cruciate and collateral ligaments as well as the popliteus muscle in order to maximize the natural anatomical stability of the joint. The anterior capsule was removed to provide adequate visibility of the joint, while leaving the lateral and posterior capsule intact.

A 4 mm diameter tunnel was drilled through the femoral condyles, parallel to the joint line in order to allow future relocation of the lateral condyle using a 4 mm bolt. A lateral femoral condyle osteotomy was performed in order to gain complete access to the lateral compartment without compromising ligament integrity. An oblique cut was made using a 0.5 mm oscillating saw blade, beginning just lateral to the femoral origin of the ACL and exiting at the lateral transition of the femoral metaphysis and diaphysis (Fig. 1A). This technique is similar to that reported by Dienst et al (11) for the lateral compartment and represents a modification of a protocol initially described by Martens et al (23) for accessing the medial compartment. Martens et al (23) demonstrated no significant change in contact mechanics after osteotomy.

Small anterior and posterior horizontal arthrotomies were made below the level of the menisci to allow insertion of 0.1 mm thick dynamic pressure-sensitive film (K-Scan 4000, maximum 1500 psi; Tekscan Inc., Boston, MA) in a technique similar to that reported by Van Thiel et al (34). Sensor pads were placed in both medial and lateral compartments and fixation of the sensors was achieved for the duration of the study using Kelly hemostatic clamps. Clamps fixed the sensors posteriorly to the posterior capsule and anteriorly to distal remnants of the anterior capsule (Fig. 1A). This dual fixation served to minimize any movement or rotation of the sensors once placed below the meniscus. Anatomical variations in the size of each specimen's meniscus led to variations in the amount of meniscus visualized by the sensors. Care was taken to place the sensors in a position that maximized the amount of visible meniscus with priority focused on including the center of the lateral compartment and the posterior meniscus. While complete visualization of the ovoid meniscus could not be achieved with square sensor pads, prior fixation of the sensor pads allowed for direct comparison of the visible intact meniscus with the same visible meniscus post-radial section.

The femur was secured to a custom jig that used smooth rods to fix the femur in precise prefabricated positions of fixation of 0° or 60° of flexion relative to the fixed tibia (Fig. 1B). These joint positions were respectively chosen to represent extension of the knee as well as a single consistent point across the normal range of flexion of the knee. The proximal femoral fixation hole was drilled through the diaphysis and the distal hole was placed through a close approximation of the axis point of flexion which aided for consistent alignment between the medial and lateral compartments through the range of motion of the specimen.

The tibia was affixed to a Taylor Spatial Frame (TSF) dynamic external fixator (Smith & Nephew, Memphis, TN) using two Shanz pins in the anteroposterior (A-P) plane and one half pin inserted at an oblique angle through the proximal tibial metaphysis at 1 cm below the joint line. The TSF is a multi-planar hexapod external fixator, used clinically for limb lengthening and deformity correction. It is composed of proximal and distal hexagonal rings connected by six adjustable struts which allow for simultaneous adjustments in translation and angulation along coronal, sagittal, and axial planes. The TSF was used in a manner similar to that previously used by Van Thiel et al (34) and the same investigator installed the TSF for all ten specimens, thereby ensuring consistent loading technique. Prior to testing, the specimen was mounted on a materials testing machine (Insight 5; MTS Corporation, Eden Prairie, MN) with the femur affixed to the custom jig in extension and the tibia fixed to the TSF. An initial load of 20N was applied, in order to visualize the initial contact pressure distribution across the joint and to ensure that the sensors were aligned over the meniscus and, when activated, could incorporate as many pixels as possible. The joint alignment of the specimen was then readjusted by manipulating the multi-planar configuration of the TSF until an approximately equal load distribution between the medial and lateral compartments was visualized. An equal load distribution across both tibial compartments was chosen over the anatomical position of 60% load borne across the medial compartment due to limitations in our lab's ability to confirm a precise load distribution between the compartments. Equal load could be visually approximated under the 20N preload, while an

exact 60%-40% load distribution could not. There was no further manipulation of the natural varus/valgus alignment of the specimen with the TSF or femoral jig. All further testing of the specimen proceeded with the fixed varus-valgus configuration that was independently determined in flexion and extension in order to maintain a consistent load distribution across both joint compartments throughout serial testing. In a manner similar to that previously described by Dienst et al (11), the TSF and thus, the tibial component, had unconstrained anterior-posterior and medial-lateral translation, internal-external rotation during the initial preconditioning load of 20N in the intact state both in flexion and in extension (Fig. 1B). At this point the TSF was fixed on the MTS to minimize anterior-posterior (A-P) shear forces of the TSF across the table at the maximum compressive load of 800N. This single point of restraint was implemented to provide some A-P translational stability to the specimen which was devoid of stabilizing musculature and to preserve presumed cruciate ligament integrity under the full 800N load.

Radially oriented defects were created 4 mm posterior to the posterior junction of the popliteal fossa of the lateral meniscus using a No. 15 blade (Fig. 2A-B). Each specimen underwent six sequential testing conditions: (1) intact lateral meniscus, (2) 50% radial width section representing a tear extending into the red-white region of the meniscus, (3) 75% radial width section representing a tear extending into the red-red region, (4) 100% radial width section representing a complete radial tear, (5) meniscal repair, and (6) total meniscectomy. One specimen from each paired set of knees was randomly chosen to receive either an inside-out repair using non-absorbable 2-0 suture (Fiberwire) or all-inside repair (Meniscal Cinch). The contralateral knee specimen received the alternate repair construct. The selections of which repair construct to perform first and whether this was performed on either a left or right knee was arbitrary. Overall, there were 5 all-inside repairs (3 left knees, 2 right knees) and 5 inside-out repairs (2 left knees, 3 right knees). All of the repairs were performed with two horizontal mattress sutures-- one crossing the tear on the superior surface of the meniscus and a second in the same configuration on the inferior surface. During the repair phase of the pilot study, specimens were manually cycled 50 times without load to verify the structural integrity of both repair constructs in the cadaveric model.

Each pressure sensor measured an area of 28 x 33 mm and provided contact area and pressure measurement from 2288 sensels (sensing elements). Per manufacturer's guidelines, contact area was defined as the sensor area containing only the loaded transducer sensels. This corresponded to the area of contact between the femur and the tibia through the meniscus. There was anatomic variability between specimens with regard to the amount of lateral meniscus that could be visualized given the constraints of the size of the pressure sensor. However, care was taken to place the sensors in a position that accommodated the greatest area of meniscus visualized during preloading then fixed in place prior to testing of the intact specimen. All results, for both medial and lateral joint compartments, were compared against this fixed sensor area, normalizing any variability in relative contact area that could be related to the specific size of the lateral

meniscus. The results data were normalized to that of the intact condition under the maximum load.

#### Testing:

Prior to each loading trial, a preload of 20N was applied for 2 minutes so that the specimen's meniscal fibers were slightly conditioned to loading. The specimen was then loaded at a rate of approximately 13N/sec until a maximum load of 800N was reached. 800N was chosen as a result of a limitation of the TSF. During pilot studies, a load of 1000N resulted in noticeable visible deformation of the two Shanz pins used in the TSF for fixation of the tibia. A load of 800N fell comfortably below this value, did not induce visible pin deformation, and represented the body weight of a 70kg person. This load was held for 60 seconds to ensure stabilization of pressure transmission across the joint. Rest time following loading was at least 2 minutes in order to aid tissue recovery. Using I-Scan software (Tekscan Inc., Boston, MA), instantaneous recordings of 10 second duration were created (Fig. 4). For each test condition, knees were tested first at 0° flexion and then at 60° flexion (corresponding to the extremes of range experienced during gait). The femoral jig is fixed and immobile within the MTS machine throughout all testing, whereas the TSF is attached to the tibia but is free to rotate and translate in a medial/lateral or anterior/posterior plane. After the specimen is tested at 0° flexion, full load is removed, the femur is rotated about the distal fixation point of the femoral jig and fixed in 60 degrees flexion. Two trials were performed per flexion angle for each meniscal testing condition to confirm reproducibility of results. Prior publications with K Scan sensors (16, 21) suggest that measurements taken with this device are reproducible with two data sets. Relative difference in contact pressure between data sets was no greater than 0.7 kg/cm<sup>2</sup> and for contact area no greater than 0.09 in<sup>2</sup>. Between each serial sectioning test condition (e.g., 50% radial tear), the specimen was allowed to rest for at least 10 minutes. During this time period, the specimen was removed from the material testing machine and the femur jig, while remaining attached to the TSF. The osteotomy site was reopened, exposing the meniscus to create the serial radial incision or repair. The exposed specimen was moistened with saline solution to prevent desiccation of the meniscus. The osteotomy was closed, taking care to ensure that the distal femur was fixed and stable. The specimen was reinserted into the femur jig and the tibia, affixed to the TSF and fastened to the base of the materials testing machine in the position of natural seating previously determined during initial testing of the intact state. For each specimen, contact pressure, peak contact force and contact area for both lateral and medial compartments was recorded, with the reported data for each meniscal condition per specimen representing the average of the two repeated trials.

#### DATA ANALYSIS

Data were analyzed using a two-factor repeated measures ANOVA with within-subject factors of repair type and test condition (e.g., intact, 75% tear, meniscectomy). The Tukey-Kramer post-hoc test for multiple comparisons was used when significant differences among the experimental conditions were detected. In an attempt to minimize the effects of anatomical

variations between specimens, all data was normalized to that of the intact state. Threshold for statistical significance was a  $p$ -value of less than 0.05.

## RESULTS

### Contact Pressure and Peak Force

A summary of normalized mean tibiofemoral contact pressure (CP) data across radial sectioning conditions as well as after repair and total meniscectomy for both the lateral and medial compartments is provided in Fig 5-A and Fig. 6-A. In 0° of flexion, there was no significant increase in contact pressure for 50% ( $p = 0.7649$ ) and 75% ( $p = 0.3619$ ) radial tear versus the intact state. Complete radial tear (100% sectioning), however, produced a significant increase in CP averaging 49% greater than in the intact meniscus ( $p < 0.0001$ ). No significant difference in lateral CP was detected between the two repair constructs ( $p = 0.4000$ ), and both repairs demonstrated decreased lateral CP relative to the complete radial tear state which was not significantly different from the intact state ( $p = 0.2595$ ). Lateral CP following total meniscectomy was significantly greater than CP following complete radial tear ( $p < 0.0001$ ), and overall, demonstrated a 100% increase in CP compared to the intact state. Results for CP in 60° of knee flexion were similar to those seen in 0° of flexion (Fig. 4-A). The medial side showed no significant difference in normalized contact pressure between all testing conditions for 0° and 60° of flexion ( $p \geq 0.2580$ ) (Fig. 5-A).

Trends in PF for both the medial and lateral compartment were similar to those seen with CP. In 0° of flexion, no significant difference was noted between the intact state and tears extending through 50% ( $p = 0.9611$ ) and 75% ( $p = 0.6366$ ) of the radial width of the lateral meniscus. Statistically significant differences were seen after complete radial transection ( $p = 0.0008$ ) and after total lateral meniscectomy ( $p = 0.0001$ ) compared to the intact state. With regards to repair, no statistically significant differences were noted across all test conditions for either repair construct ( $p = 0.1037$  when compared to the intact state) and no significant difference in lateral PF was detected between the two repair constructs ( $p = 0.1377$ ). However, peak force values for both repairs were consistently lower than those recorded for 100% radial tear and total meniscectomy which is consistent with trends seen in CP. Results for PF in 60° of knee flexion were similar to those seen in 0° of flexion.

### Contact Area

Normalized results for lateral and medial compartment contact area are presented for all testing conditions in Fig. 4-B and Fig. 5-B. Lateral contact area (CA) did not significantly change following 50% ( $p = 0.3832$ ) and 75% sectioning ( $p = 0.6269$ ) compared to the intact state. However, a significant decrease in CA (47% in 0° of flexion) was seen after complete radial tear compared to the intact state ( $p < 0.0001$ ). Meniscal repair produced an increase in CA compared with complete tear; however, CA after either meniscal repair was still significantly less (22% in 0° of flexion) than that of the intact meniscus ( $p < 0.0001$ ). No significant difference in CA was noted between the repair types ( $p = 0.7659$ ). Post-meniscectomy CA was significantly smaller

than after complete radial tear ( $p = 0.0023$ ). Results for CA in 60° of knee flexion were similar to those in 0° of flexion (Fig 5-A). The medial side showed no significant difference in normalized contact area between all testing conditions for 0° and 60° of flexion ( $p \geq 0.0650$ ) (Fig 5-B).

## DISCUSSION

The purpose of this study was to evaluate knee contact pressures with sequential sectioning of the lateral meniscus as well as inside-out and all-inside repair techniques for complete radial tears. Results demonstrated a significant increase in lateral compartment contact pressure as well as a significant decrease in contact area following complete radial tear in a static human cadaveric model at zero and sixty degrees of flexion. Interestingly, lesser degrees (i.e., up to 75%) of radial tear were shown to exhibit similar contact pressure profiles to those of the intact meniscus in our two conditions. These findings reinforce the importance of peripheral meniscal fibers and are in agreement with the observations of Bedi et al (8) who demonstrated that there was no significant difference in peak contact pressure between the intact medial meniscus and radial tears up to 90% of the radial width ( $p < 0.095$ ).

There is limited biomechanical data on the effect of a complete lateral radial tear (33). Shrive et al (33), in human cadaveric and porcine models, noted similar load transmission in meniscectomized knees and those with complete radial tears of both menisci. Although, they utilized a testing protocol in which the collateral ligaments were sectioned and independent testing of radial tears of the lateral meniscus was not included. Furthermore, Marzo et al (24) and Allaire et al (1) demonstrated significant increases in contact pressures resulting from simulated posterior root avulsion of the medial meniscus with results from Allaire et al (1) demonstrating equivalence to meniscectomy. Similarly, Paletta et al (29) found no significant difference in peak pressures between meniscectomy and those after transection of the anterior and posterior horns of the lateral meniscus.

The current study did demonstrate statistically significant differences following complete radial tears, but these changes were not equivalent to those accompanying total meniscectomy. Complete radial tear produced significantly smaller changes in normalized contact pressure (average 43% vs. 99%), peak force (avg. 29% vs. 40%), and contact area (avg. 47% vs. 63%) compared to total meniscectomy. Numerous studies have demonstrated the effects of total meniscectomy (5, 6, 17, 21), and our results are in agreement with the consistently observed decrease in contact area and increase in pressure transmission. Paletta et al (29) and Fukabayashi et al (14) reported large increases in peak force (100% to 335%) following lateral meniscectomy, however, results in the study by Dienst et al (11) were more consistent with our own (34-46%). Decrease in contact area in our study was similar to that seen by Paletta et al (29) and Fukabayashi et al (14) (45 to 50% versus 60 to 65%). However, details of testing conditions are fairly variable across these comparable studies. It is possible that each study's variations in load transmission, use of different pressure sensing materials, in types of specimens tested (human vs. porcine) as well as intrinsic anatomic variability between human cadaveric specimens could make direct comparison of their results with the results of our study difficult. There was no significant



change across all joint-loading variables in the contralateral medial compartment. This result was consistent with what has been reported in the contralateral hemi-joint in a similar study by Marzo et al (24).

Meniscal repair of a complete radial tear demonstrated greater contact area (12% to 26%, depending on the specific repair technique) compared to the complete radial tear, however, contact area after repair remained significantly less (20% to 34%) than for the intact meniscus. This was most likely due to the fact that the repair construct improves, but cannot replicate the load sharing that an intact meniscus provides through its radial fibers. With regard to contact pressures; each of the repair states was not significantly different than the intact state, and were significantly less than the complete tear or meniscectomized state. Relatively few other studies have examined the biomechanical effects of meniscal repair. Allaire et al (1) and Marzo et al (24) noted that repair of root avulsion demonstrated restoration of load transmission equal to the intact meniscus. Bedi et al (8) noted no significant difference following inside-out meniscal repair compared to the intact medial meniscus and radial tears involving up to 90% of the radial width. In our study, contact pressure and peak force decreased following both inside-out and all-inside repair techniques and contact pressures after both repair techniques were not significantly different from the intact state at time zero. There was no demonstrable difference between the two meniscal repair techniques for any of the measured parameters.

Further discussion of our method of specimen fixation is warranted. The TSF was used instead of the more common practice of potting using PMMA cement or resin (11, 23, 36). During early stages of pilot testing within our lab, the tibia and fibula were cemented into a polyvinyl chloride (PVC) pipe using PMMA, with effort taken to ensure that the tibial plateau remained parallel to the MTS testing platform. However, using this method, it was exceedingly difficult to verify appropriate weight distribution across the tibial plateau until placement of Tekscan sensors prior to testing of the intact state. A malaligned specimen at this junction in testing would have required repotting of the specimen after osteotomy and sensor placement. Removal of the PMMA cement would have placed a specimen at considerable risk for fracture, rendering it unusable for testing. Usage of the TSF minimized the potential for excessive overloading of either compartment of the knee during initial fixation of the tibia and allowed for translational and rotational adjustments, if needed, of the alignment of tibial plateau following placement within the testing apparatus and prior to compressive loading of the specimen.

#### Limitations

Our study is not without limitations. The protocol employed a static loading model that was adapted from widely accepted experimental techniques (1, 11, 14, 17, 21, 24, 29) and has previously demonstrated reproducible and reliable results (34). However, this approach has two important limitations. In vivo, the pressure and contact area of the lateral compartment varies with knee position/loading and each repair construct would only be clinically functional if it remains secure throughout dynamic loading. The effects of dynamic loading were not tested in the current study. However, prior investigations on the effect of cycling a meniscal repair have

noted a non-linear relationship with gap formation occurring in the early cycles of testing (25, 40). Therefore, in order to compensate for this phenomenon, each knee/repair construct was manually cycled 50 times prior to testing. The static loading conditions were then chosen based on previous published work (1, 11, 14, 17, 21, 24, 29). The authors acknowledge the shortcomings associated with non-dynamic conditions, but also believe that the testing protocol employed did allow for a well-controlled analysis of the contribution from the lateral meniscus on the contact pressure profile of the knee at 0 and 60 degrees.

Another limitation was that our methods of specimen fixation used an approximately equal load distribution across both medial and lateral compartments, which slightly differ from other studies (34) and does not represent true anatomical alignment of the knee of which there is preferential loading across the medial compartment (60% of load distribution). We do not believe this would significantly alter the results of our study because each specimen was subjected to all test conditions in this standardized alignment configured for the intact specimen and all results were normalized to this intact state.

The Tekscan sensors were chosen for data collection due to advantages in reproducibility, dynamic measurement and reusability compared to Fuji Film. The limitations of Tekscan include the finite thickness of the sensor which may affect contact pressure and area measurements, decreased sensor durability under severe loads, and the inability to customize the sensor shape to the desired specifications. The rectangular shape of the Tekscan sensor resulted in an additional limitation because the coronary ligaments of the menisci were cut in order to facilitate accurate placement of the sensors. This was also standardized across all testing conditions and would most likely not influence the results reported. While we acknowledge these potential limitations, they conform to those described in previous biomechanical knee studies (21, 24)

One clinical limitation was that we tested all conditions in a cadaver model. Inherent to any cadaver study, the effects of healing and rehabilitation following repair cannot be measured and clinical outcomes of radial tear and repair could not be considered. Additionally, our protocol standardized the location of radial transection, limiting it to the posterior segment of the lateral meniscus. Thus, we cannot confidently extrapolate our results to the scenario of radial tears of the anterior segment or midbody of the lateral meniscus.


#### Clinical Implications

Although complete radial tear was not equivalent to total meniscectomy in any of the parameters measured, increases in pressure transmission were demonstrated with greater than a 75% tear. Furthermore, repair of the complete radial tear using an all-inside or inside-out construct did improve the time zero biomechanical contact pressure profile, but did not return the contact area to the intact state. These findings are clinically important because the detrimental effect of elevated pressure on cartilage is well established (12, 30). If repair of a complete radial tear at time zero in a cadaver model improves pressures, further investigation in a clinical model is warranted. This is supported by the clinical fact that Yagishita et al (38) observed healing in

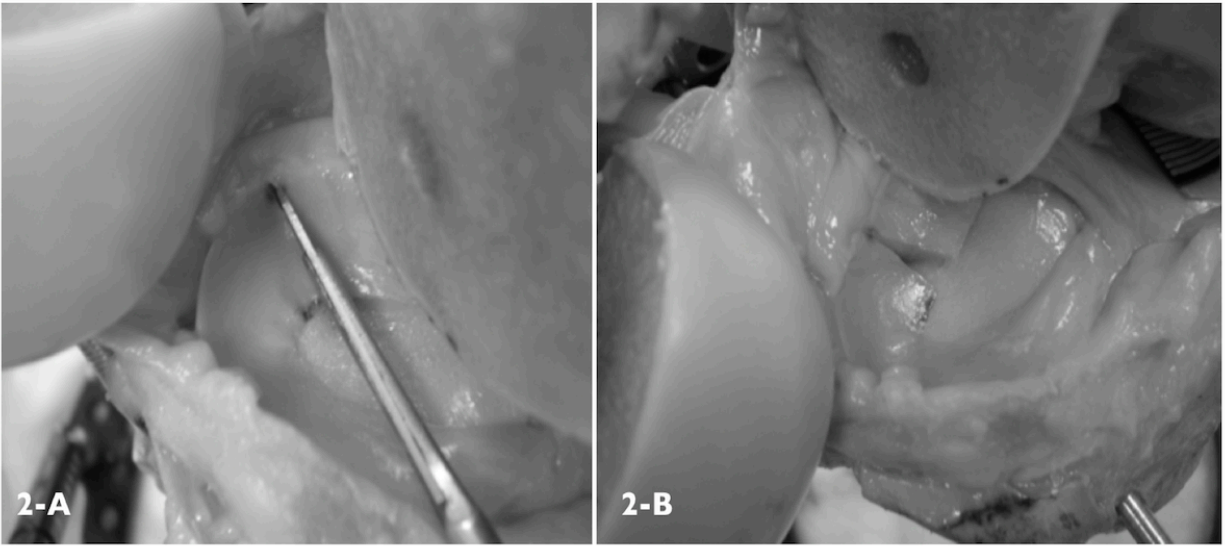
many lateral meniscal tears on second look arthroscopy (78% to 94%), but identified no evidence of healing in the three complete lateral radial tears left *in situ* at the time of ACL reconstruction. Interestingly, Shelbourne et al (32) analyzed a cohort of ACL reconstructions with and without posterior lateral meniscus root (PLMR) tears at a minimum of 5 years follow up, and found that the patients with meniscal tears had a trend toward worse functional scores and significantly decreased lateral joint space. Certainly, at time zero, our data provides a biomechanical rationale for repair of complete radial meniscal tears. Long term clinical results of repair remains to be demonstrated, however, at short term second look arthroscopy, both van Trommel et al (35) and Yoo et al (39) noted some degree of healing of the lateral meniscus following repair of complete radial tears. Yoo et al had complete healing in all cases, but even with the addition of fibrin clot van Trommel et al reported that 40% (2/5) had incomplete healing treated with partial meniscectomy.

Overall, both inside-out and all-inside repair of a complete radial tear showed significant improvements in contact pressures of the lateral compartment at time zero in a static cadaveric knee model. This supports the clinical findings that an intact meniscus is superior (32), and encourages further clinical investigation into the repair of radial tears (35, 39). Additionally, the minimal contact pressure changes seen with less than a 75% tear suggest that the clinical maintenance of the peripheral fibers may be important and the ideal management of non-complete tears could be different than complete tears. Future studies will include the evaluation of the effect of partial lateral meniscectomy on knee biomechanics and the clinical outcomes of posterior lateral meniscal radial repair.

## FIGURES



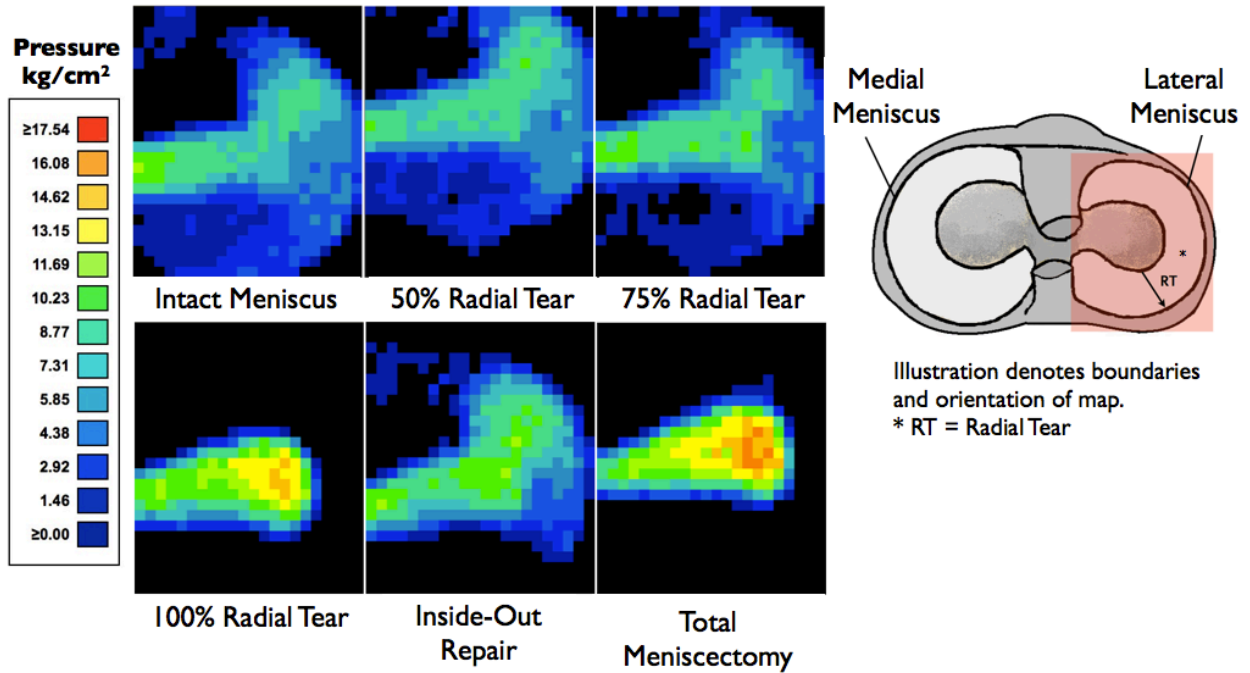
**Figure 1: (A)** Specimen preparation involving lateral condyle osteotomy, external tibial fixation and sub-meniscal placement of pressure-sensitive film.  
**(B)** Each specimen fixed to a custom femoral jig and loaded to 800 N using a material testing machine (MTS Insight 5). Specimen shown in 60° flexion. Arrows illustrating degrees of freedom of motion of TSF:  
(A-P = Anterior-Posterior; L-M = Lateral-Medial; R = Internal-External Rotation)

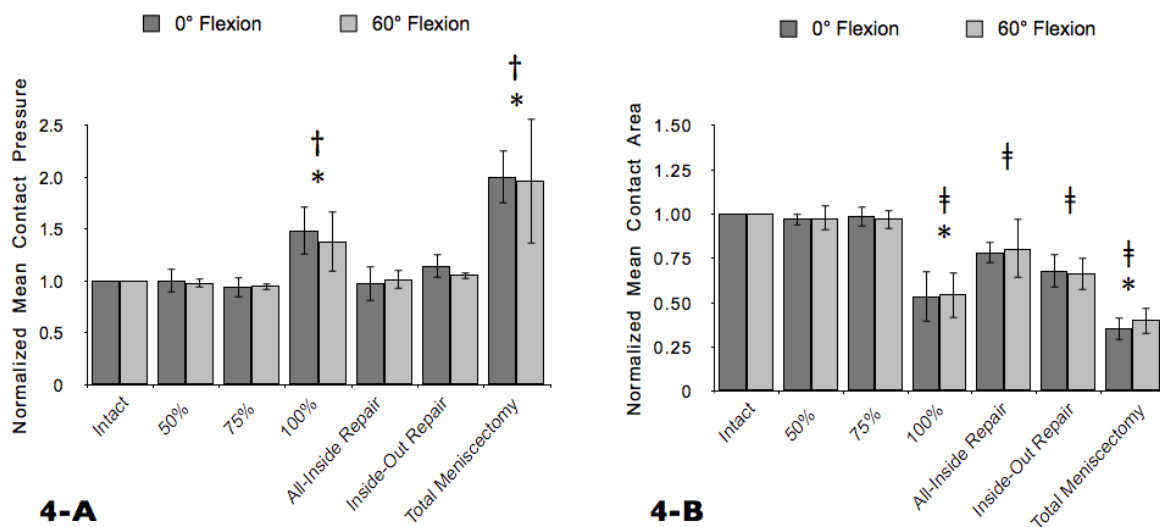


**Figure 2:** (A) Creation of radially-oriented defect in posterior-lateral aspect of lateral meniscus; (B) Complete (100%) radial tear

**Figure 3: Sequential contact pressure maps of lateral compartment for specimen #5.**

Increases in pressure or changes in pressure distribution denoted by color changes  
(See legend for pressure range)





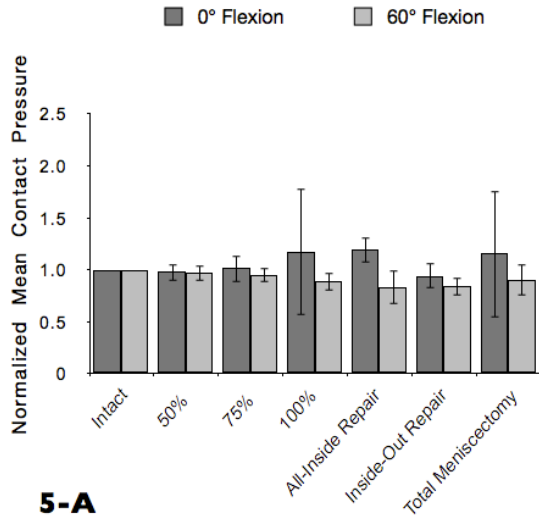
**Figure 4: Normalized Mean Contact Pressure and Contact Area Across the Lateral Compartment**

Normalized mean contact pressure **(A)** and mean contact area **(B)** across the lateral compartment in extension (0° flexion) and 60° flexion.

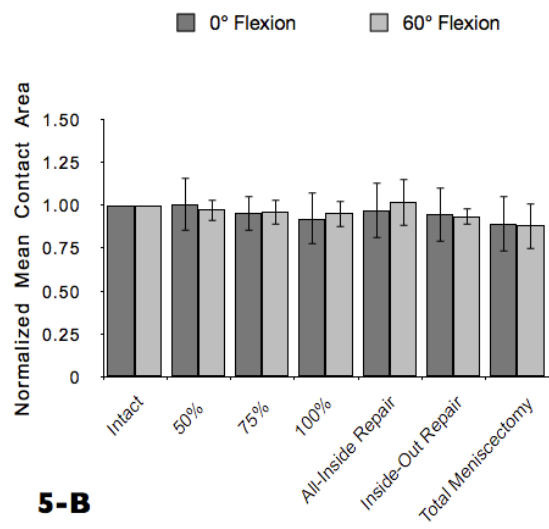
† 100% radial tear and total meniscectomy were significantly different from the intact state ( $p < 0.001$ ).

‡ 100% radial tear, all-inside repair, inside-out repair and total meniscectomy were significantly different with respect to the intact state ( $p < 0.001$ ).

\* A significant difference existed between 100% radial tear and total meniscectomy ( $p < 0.001$ ).



**5-A**



**5-B**

**Figure 5: Normalized Mean Contact Pressure and Contact Area Across the Medial Compartment**

Normalized mean contact pressure **(A)** and mean contact area **(B)** across the medial compartment in extension (0° flexion) and 60° flexion.

\*All labeled conditions (Intact - Total Meniscectomy) refer to testing conditions on lateral meniscus. No significant difference exists between all tested states across the medial compartment during serial sectioning of the lateral meniscus.



## REFERENCES

1. Allaire R, Muriuki M, Gilbertson L, Harner CD. Biomechanical consequences of a tear of the posterior root of the medial meniscus. Similar to total meniscectomy. *J Bone Joint Surg Am.* 2008;90(9):1922-1931.
2. Alford JW, Lewis P, Kang RW, Cole BJ. Rapid progression of chondral disease in the lateral compartment of the knee following meniscectomy. *Arthroscopy.* 2005;21:1505-1509.
3. Allen PR, Denham RA, Swan AV. Late degenerative changes after meniscectomy. Factors affecting the knee after operation. *J Bone Joint Surg Br.* 1984;66(5):666-671.
4. Andary J, Zvijac JE, Hechtman KS, Martinez A, Schurhoff MR, Green JB, Uribe JW. Radial tears of the lateral meniscus: the case for repair. *Arthroscopy.* 2003;19(6), Supplement 1:86.
5. Baratz M, Fu FH, Mengato R. Meniscal tears: The effect of meniscectomy and of repair on the intraarticular contact areas and stress in the human knee. *Am J Sports Med.* 1986;14(4):270-275.
6. Baratz M, Rehak DC, Fu FH, Rudert MJ. Peripheral tears of the meniscus: The effect of open versus arthroscopic repair on the intraarticular contact stress in the human knee. *Am J Sports Med.* 1988;16(1):1-6.
7. Beaupre A, Choukroun R, Guidouin R, Garneau R, Gérardin H, Cardou A. Knee Menisci: Correlation between microstructure and biomechanics. *Clin Orthop Relat Res.* 1986;208:72-75.
8. Bedi A, Kelly NH, Baad M, Fox AJ, Brophy RH, Warren RF, Maher SA. Dynamic contact mechanics of the medial meniscus as a function of radial tear, repair, and partial meniscectomy. *J Bone Joint Surg Am.* 2010;92:1398-1408
9. Cho SD, Ko SH, Woo JK. Meniscus-Stabilizing Function of the Meniscofemoral Ligament: Experimental Study of Pig Knee Joints. *Arthroscopy.* 2006; 22 (8): 872-877
10. Choi NH, Kim TH, Son KM, Victoroff BN. Meniscal Repair for Radial Tears of the Midbody of the Lateral Meniscus. *Am J Sports Med.* 2010; 38(12):2472-6
11. Dienst M, Greis PE, Ellis BJ, Bachus KN, Burks RT. Effect of lateral meniscal allograft sizing on contact mechanics of the lateral tibial plateau: an experimental study in human cadaveric knee joints. *Am J Sports Med.* 2007;35(1):34-42.
12. Ewers BJ, Dvoracek-Driksna D, Orth MW, Haut RC. The extent of matrix damage and chondrocyte death in mechanically traumatized articular cartilage explants depends on rate of loading. *J Orthop Res.* 2001;19(5):779-784.
13. Fairbank TJ. Knee joint changes after meniscectomy. *J Bone Joint Surg Am* 1948;30B(4):664-670.
14. Fukubayashi T, Kurosawa H. The contact area and pressure distribution pattern of the knee. A study of normal and osteoarthritic knee joints. *Acta Orthop Scand.* 1980;51(6): 871-879.
15. Grood ES, Meniscal function. *Adv Orthop Surg* 1984;7:193-197.

16. Harris ML, Morberg P, Bruce WJ, Walsh WR. An improved method for measuring tibiofemoral contact areas in total knee arthroplasty: a comparison of K-scan sensor and Fuji film. *J Biomech.* 1999;32(9):951-958.
17. Ihn JC, Kim SJ, Park IH. In vitro study of contact area and pressure distribution in the human knee after partial and total meniscectomy. *Int Orthop.* 1993;17(4):214-218.
18. Johnson RJ, Kettelkamp DB, Clark W, Leaveron P. Factors affecting late results after meniscectomy. *J Bone Joint Surg Am.* 1974;56(4):719-729.
19. Jorgensen U, Sonne-Holm S, Lauridsen F, Rosenklint A. Long-term follow-up of meniscectomy in athletes. A prospective longitudinal study. *J Bone Joint Surg Br.* 1987;69(1) 80-83.
20. Kousa P, Jarvinen TL, Pohjonen T, Kannus P, Jarvinen M. Initial fixation strength of a biodegradable and titanium screws in anterior ligament reconstruction: biomechanical evaluation by single cycle and cyclic loading. *Am J Sports Med.* 2001;29:420-425.
21. Lee SJ, Aadalen KJ, Malaviya P, Lorenz EP, Hayden JK, Farr J, Kang RW, Cole BJ. Tibiofemoral contact mechanics after serial medial meniscectomies in human cadaveric knee. *Am J Sports Med.* 2006;34(8):1334-1344.
22. Lerer DB, Umans HR, Hu MX, Jones MH. The role of meniscal root pathology and radial meniscal tear in medial meniscal extrusion. *Skeletal Radiol.* 2004;33(10):569-574.
23. Martens TA, Hull ML, Howell SM. An in vitro osteotomy method to expose the medial compartment of the human knee. *J Biomech Eng.* 1997;119(4):379-385.
24. Marzo JM, Gurske-DePerio J. Effects of medial meniscus posterior horn avulsion and repair on tibiofemoral contact area and peak contact pressure with clinical implications. *Am J Sports Med.* 2009;37(1):124-129.
25. Mehta VM, Terry MA. Cyclic testing of 3 all-inside meniscal repair devices: a biomechanical analysis. *Am J Sports Med.* 2009;37(12):2435-2439.
26. Messner K, Gao J. The menisci of the knee joint. Anatomical and functional characteristics, and a rationale for clinical treatment. *J Anat.* 1998;193:161-178.
27. Miller M, Warner J, Harner CD. Meniscal repair. In Fu FH, Vince KG, Harner CD, eds: *Knee Surgery.* Baltimore, MD: Williams & Wilkins, 1994.
28. Newman AP, Anderson DR, Daniels AU, Dales MC. Mechanics of the healed meniscus in a canine model. *Am J Sports Med.* 1989 17 (2): 164
29. Paletta GA Jr, Manning T, Snell E, Parker R, Bergfeld J. The effect of allograft meniscal replacement on intraarticular contact area and pressures in the human knee. A biomechanical study. *Am J Sports Med.* 1997;25(5):692-698.
30. Quinn TM, Allen RG, Schalet BJ, Perumbuli P, Hunziker EB. Matrix and cell injury due to sub-impact loading of adult bovine articular cartilage explants: effects of strain rate and peak stress. *J Orthop Res.* 2001;19(2):242-249.
31. Ravallin RV, Mazzocca AD, Grady-Benson JC, Nissen CW, Adams DJ. Biomechanical comparison of patellar tendon repairs in a cadaver model: an evaluation of gap formation at the repair site with cyclic loading. *Am J Sports Med.* 2002;30:469-473.

32. Shelbourne KD, Roberson TA, Gray T. Long-Term Evaluation of Posterior Lateral Meniscus Root Tears Left In Situ at the Time of Anterior Cruciate Ligament Reconstruction. *Am J Sports Med.* 2001 20 (10)
33. Shrive NG, O'Connor JJ, Goodfellow JW. Load-bearing in the knee joint. *Clin Ortho and Relat Res.* 1978;131:279-287.
34. Van Thiel GS, Frank RM, Gupta A, Ghodadra N, Shewman EF, Wang VM, Bach BR, Verma NN, Cole BJ, Provencher MT. Biomechanical evaluation of a high tibial osteotomy with a meniscal transplant. *J Knee Surg.* 2011 Mar; 24(1):45-53.
35. van Trommel MF, Simonian PT, Potter HG, Wickiewicz TL. Arthroscopic meniscal repair with fibrin clot of complete radial tears of the lateral meniscus in the avascular zone. *Arthroscopy.* 1998;14(4):360-365.
36. Verma N, Kolb E, Cole BJ, Berkson E, Garretson R, Farr J, Fregly B. The Effects of Medial Meniscal Transplantation Techniques on Intra-Articular Contact Pressures. *J Knee Surg.* 2008;21:20-26.
37. Wroble RR, Henderson RC, Champion ER, el-Khoury GY, Albright JP. Meniscectomy in children and adolescents: A long-term follow-up of study. *Clin Orthop Relat Res.* 1992;279:180-189.
38. Yagishita K, Muneta T, Ogiuchi T, Sekiya I, Shinomiya K. Healing Potential of Meniscal Tears Without Repair in Knees With Anterior Cruciate Ligament Reconstruction. *Am J Sports Med.* 2004; 32 (8): 1953
39. Yoo JC, Ahn JH, Lee SH, Lee SH, Kim JH. Suturing complete radial tears of the lateral meniscus. *Arthroscopy.* 2007;23(11):1249.e1-7.
40. Zantop T, Eggers AK, Musahl V, Weimann A, Petersen W. Cyclic testing of flexible all-inside meniscus suture anchors: biomechanical analysis. *Am J Sports Med.* 2005;33(3):388-394.